



## Bite Raisers in Orthodontics: A review

Nabaa Qais Raisan, B.D.S.\*

Mohammed Nahidh, B.D.S., M.Sc.\*\*

\*General Dentist, Ministry of Health, Baghdad, Iraq, Mobile: 009647505272452

\*\*Professor, Department of Orthodontics, College of Dentistry, University of Baghdad, Baghdad, Iraq. e-mail: [m\\_nahidh79@yahoo.com](mailto:m_nahidh79@yahoo.com), Mobile: 009647702551616, ORCID ID: 0000-0003-0155-418X

### Abstract

**Aim of the study:** This study aimed to review the various types of bite raisers used in daily orthodontic practice, their advantages and disadvantages, the fabricated materials, and the biomechanics for each use.

**Methods:** Searching for different types of bite raisers and their applications, indications, and benefits was carried out using different databases, including PubMed Central, Science Direct, Wiley Online Library, the Cochrane Library, Textbooks, Google Scholar, Research Gate, and hand searching till March 2022. After excluding the duplicate articles, information in these papers is summarized and in forms of types, indications, advantages, disadvantages, and effects.

**Results and Conclusions:** There are many types of bite raisers, of which the fixed one is the most applicable as it does not need the patients' cooperation, yet the material of choice and the type of malocclusion in the case itself may influence the location, type of the material used, its thickness and the purpose of its use. Orthodontists use the most uncomplicated technique to open the bite allowing easy teeth movement.

**Keywords:** Bite raisers, Bite turbos, Bite planes, Orthodontics.

### Introduction

#### Definitions

According to Daskalogiannakis <sup>(1)</sup>, occlusion is the functional contact between the maxillary and mandibular teeth, whereas disarticulation separates the mandible from the maxilla through tooth-guided contacts. An orthodontic bite raiser is a specially produced artificial surface put either posteriorly or anteriorly to provide a plane against which the opposing arch's teeth might contact throughout occlusion, preventing complete jaw closure <sup>(2)</sup>.

#### Nomenclatures

Bite turbo, bite ramp, bite block, bite pillow, bite build-up, bite builder, bite opener, bite jump, bite plane, bite plate,

occlusal pad, speed or bite bumps, disarticulator, and deprogrammer <sup>(3)</sup>.

#### Historical Development of Bite Raisers

In 1771, John Hunter described the first inclined plane, made of wrought silver and used to repair lingually blocked out teeth on lower anterior teeth. In 1803, Fox created a posterior bite plane by inserting acryl blocks on posterior teeth to alleviate the force of occlusion prior to moving teeth <sup>(4)</sup>.

In 1883, Henry Clay Quinby depicted a maxillary bite plate that relieved pressure on back teeth, allowing them to elongate. Also, the above author determined that reducing the anterior overbite can allow the upper incisors to shift more lingually <sup>(4)</sup>.

In 1889, W. G. Bonwill described and drew a maxillary biting plate. The goal has been to get the inferior incisors up into the sockets while allowing molars and bicuspids to come down and antagonize prior to removing the plate<sup>(4)</sup>.

The first maxillary inclined plane reported in the literature to jump the bite was N. W. Kingsley's bite plane, which was indicated in 1892. In 1879, Kingsley discussed the biting plane but did not detail it. Even though he did not mention it, his bite plane, like the flat maxillary plane, might have had the impact of reducing overbite<sup>(5)</sup>. Using such a device, the mandible was moved forward bodily from posterior Class II to typical Class I relation.

Dr. Edward Angle used a plane and spur to retain cases where the bite was jumped using the Kingsley bite plate<sup>(6)</sup>.

Suggett<sup>(7)</sup> outlined the numerous applications of the inclined plane in treating malocclusion in 1915. Grieve reported a buccal inclined plane combined with a pin appliance as a mandibular growth stimulator in 1927<sup>(8)</sup>. Ormco Corporation's Joe Mayes developed a metal bite turbo as an alternative to acrylic biteplate in 1997. Mayes' design has been based on a simple lingual upper incisor bracket modification<sup>(9)</sup>.

Dr. Güray created a temporary bite raiser of 0.040" stainless steel wire that was suited to the occlusal surface of the maxillary first molar in 1999<sup>(10)</sup>.

Although many types are found, no study compares the effect of different forms on the wearing of the teeth, T.M.J., and oro-facial functions.

### Indications of Disarticulation

Singh *et al.*<sup>(3)</sup> listed down the main indications of disarticulation:

1. When using ceramic brackets, protect brackets from debonding and teeth from attrition.
2. Specific sorts of malocclusions that impact the three planes of space are treated.

3. Unlocking occlusion for the transverse or anteroposterior correction.
4. Preventing specific unwanted tooth movement.
5. Managing a few temporomandibular disorders.
6. Anchorage reinforcement.
7. Aids in managing occlusal cant and asymmetry.
8. Stop the functional shift (because of premature contact).

### Complications of Disarticulation

There are numerous difficulties or drawbacks associated with disarticulation<sup>(3)</sup>:

1. Breakages and wear
2. Discomfort (speech/eating problems).
3. Traumatic occlusion, periodontal problem, and mobility of teeth.
4. Space opening.
5. Unwanted teeth movements like extrusion, intrusion, and lingual inclination.
6. Loss of vitality.
7. Occlusal cant.
8. Functional shift.
9. Temporomandibular disorder symptoms.
10. Bruxism.

### Classification of Bite Raisers

Bite raisers are divided into two kinds based on their location: posterior and anterior. Furthermore, they can also be divided into removable, fixed, and semi-fixed categories, with two subtypes based on their function: flat or passive and inclined or functional<sup>(11)</sup>. Each variety will be described in detail further down.

#### 1. Anterior Bite Raisers

In the case when changes and disocclusion in the posterior dentition are needed, such as in deep bite cases caused by reduced lower facial height and infra-eruption of posterior teeth, or in the case where the posterior contact disengagement is needed for correcting posterior cross-bite and maxillary

expansion, an anterior bite plane is usually indicated<sup>(11)</sup>.

### Fixed Anterior Bite Raisers

#### **A. Lingual Brackets**

Fine, in 1991<sup>(12)</sup> used orthodontic lingual brackets as a bite raiser by bonding them on the palatal surface of the maxillary incisors. For both the practitioner and the patient, such a procedure has shown to be straightforward, cost, and time-effective (Figure 1A). Patients have indicated a quick adjustment to the lingual brackets with minor masticatory function changes<sup>(12)</sup>. With the presence of new materials and advanced technologies, the use of lingual brackets is wholly diminished; moreover, there is a possibility of enamel attrition of the lower teeth upon contact with these brackets.

#### **B. Metal Bite Turbos**

Mayes of Ormco Corporation invented metal bite turbos in 1997 (Figure 1B). It has been a straightforward alteration of Fine's lingual upper incisor bracket.

Mayes<sup>(9)</sup> listed down the advantages of his metal turbos:

1. Durable and simple.
2. Brackets could be placed upon the lower anterior earlier.
3. Posterior occlusions are freed up, which allows for faster orthodontic movement.
4. Occlusal interference preventing mandibular growth is removed by freeing up the mandible.
5. Deprogramming can help with both extracapsular and intracapsular muscle and disk disorders.
6. Removal is as simple as the removal and cleanup of a lingual bracket.

It was often complicated to place due to the varying lingual anatomy of the upper incisors, as well as lisping and unbearable tooth vibrations; it may also be broken and was not adjustable.

The results of the latest randomized clinical trial comparing the effectiveness of the reverse curve of Spee archwire and metal

anterior bite turbos in treating deep overbite cases revealed that the two methods have been efficient in deep overbite correction, with the anterior bite turbos group showing less proclination and intrusion of lower anterior, an increase in lower facial height, and shorter treatment time<sup>(13)</sup>.

#### **C. Bite Builder/ Bite Jump**

It is made from a tooth-colored polyurethane material with a curved base optimizing its lingual placement (Figure 1C). It is designed to open deep bites about 5 mm with immediate results while protecting bare enamel. It can bond lingually to upper incisors to eliminate occlusal interference and reduce bond failure on lower brackets<sup>(14)</sup>. Some types are provided with guiding tips to facilitate the bonding, and this can be removed easily after curing adhesive materials<sup>(15)</sup>. The primary issue with type is the breakage in those with heavy occlusion.

#### **D. BiTurbo**

The first BiTurbo was introduced in 2014. It featured a groove in the long axis of a bondable bite opening device to allow a periodontal probe or another instrument for positioning and press-bonded BiTurbo to enamel more accurately and efficiently (Figure 1D).

The first generation was made as a single-piece bracket, then after, Voudouris et al.<sup>(16)</sup> enhanced the first-generation BiTurbo (BT1) and created the BT2 as a 4-piece unit, which included:

1. Bracket body with vertical groove (i.e., a split), with an incisal surface curvature
2. Separate 80-gauge mesh for higher strength of the bond.
3. For better bond strength, curved bonding pads complement and conform to the curved palatal anatomy of the upper central incisor.
4. Braze (for flexibility)

### E. Button Bite Turbo

With dental wax, orthodontic buttons are attached to the palatal surface of the upper anterior teeth on dental models. A 3 mm thickness of cold cure acrylic is applied over the waxed up lingual buttons, then button bite turbo is extracted and dewaxed, polished and finished, and directly bonded prior to the appliance bonding (Figure 1E)<sup>(17)</sup>. This method is time-consuming, and the acrylic may still release residual monomers.

### F. Anterior Resin Turbos

Due to the inadequacies of metal turbos, a new turbo type has been developed: resin turbos (Figure 1F). Turbos could be made with various materials, including band cement, acrylic gels, lingual retainer adhesive, and bracket adhesives<sup>(11)</sup>. They could be made chair-side, either directly or indirectly, or 3D customized<sup>(18,19)</sup>.

Although anterior resin turbos are recommended for low-angle patients, they must be utilized with caution in high-angle instances due to the danger of unwanted posterior extrusions<sup>(3)</sup>. The lingual aspect of the upper central incisors is the most common anterior resin turbos' site. The occlusal forces are distributed by bonding the two central incisors. Due to their small roots, upper lateral incisors are infrequently used, though they can be utilized when the patient develops a lisp. The deeper the bite, the more incisal position of the turbo. They must be sufficiently long to prevent the lower arch from slipping behind it or moving the gingival to a thicker tooth part and allowing for a more forward closure course<sup>(11)</sup>. Long turbos could be put on maxillary cuspids at first to limit fracture risk, then shifted to central incisors when the overjet is decreased.

Nevertheless, this might result in the mandible moving sideways, asymmetric condylar position, and T.M.J. pain in the patient. Based on how deep the initial overbite is, turbos should be used for six months on average. On the other hand, clinicians must keep a close eye on the

periodontal health of the mandibular incisors<sup>(3)</sup>.

Turbos that have been beveled are referred to as functional turbos. They are made with beveled occluding surfaces guiding opposing teeth into proper positions. The most typical use of these applications is to correct a minor anterior crossbite. The incisal edges of two or four lower incisors are bonded with resin turbo material, which is then lingually beveled. Upper incisors are forced forwards, and the lower jaw is posteriorly directed when they contact the beveled surface (Figure 1G). In most cases, a dental crossbite can be corrected in 3 months<sup>(20)</sup>. The periodontal health of the lower incisors needs to be studied with this type.

### G. Modified Nance Palatal Button or Fixed Anterior Acrylic Bite Plate

The bite plate is a modified Nance appliance form, also known as the palatal acrylic button (Figure 1H). This appliance has been considered instrumental as a treatment accelerator since it allows brackets to be placed on the lower anterior teeth immediately, even though oral hygiene is a significant concern with this appliance<sup>(21)</sup>.

#### Removable Anterior Bite Raisers

##### A. Hawley Anterior Bite Plate

It is a typical Hawley appliance with an additional acrylic platform in the anterior zone behind the upper incisor teeth, perpendicular to the occlusal plane and teeth long axis, causing lower incisor intrusion<sup>(22)</sup>. The lower incisor bites on that plane, resulting in the formation of a gap between back teeth, which allows for posterior teeth eruption, dependent upon alveolar bone formation. The new bone must be gradually conditioned to bear mastication stresses by removing the biting plate<sup>(23)</sup>.

Those bite planes cause a differential eruption of posterior teeth, resulting in a decrease of deep bite with relative intrusion of anterior teeth (due to proclination), resulting in a leveling of the Spee curve. Furthermore, after using this plane, the

alleviation of clicking, pain, and other joint symptoms have been noted in several cases of temporomandibular disorders. The unloading of the joint, lateral pterygoid muscle relaxation and other elevators, and neuro-muscular de-programming are some of the causes of this<sup>(22,23)</sup>. Furthermore, in cases of the posterior dental cross-bite, teeth disocclusion allows for simple treatment with cross elastics.

The anterior bite plane height must not obstruct freeway space, and there must be 2-3 mm of space in the posteriors. When the gap between the posterior teeth is greater than 3 mm, patients may place their tongue in it, preventing the teeth from freely erupting (Figure 2A). On the other hand, high anterior bite planes could produce undue pain and stress to masticatory muscles, T.M.J.s, and lower incisors, resulting in an undesirable clockwise rotation of the mandible which is not ideal<sup>(3)</sup>.

### B. Sved Bite Plane

Sved<sup>(24)</sup> introduced a new bite plane, the Sved bite plane, in 1944 to lessen the adverse effects of upper incisor proclination (Figure 2B). The acrylic plate has been extended up to the incisal edge of the upper anterior, preventing the forward force component and minimizing anterior proclination.

### C. Bite Plate with Expansion Screw

For patients with a transverse deficit in the mixed dentition stage, using a removable appliance with a jackscrew and anterior bite plate (Figure 2C) has been proven effective in treating deep bites<sup>(22)</sup>.

### D. Anterior Inclined Bite Plane

It is comparable to the flat anterior bite plane, with the addition of the anterior incline plane to engage lower incisors and cause anterior movement of the mandible (Figure 2D). Growing children who have mild superior protrusion, deep bites, and mandibular retrusion benefit from the reverse incline appliance. It is also employed

following active functional therapy like twin block as a retention appliance<sup>(25)</sup>.

The upper anterior inclined plane encourages mandibular teeth to shift forward from distal to the neutral occlusion. Lower incisal edge indentations could be inserted in the bite plane to 'lock' lower incisors in the wanted forward position of the mandible<sup>(22,23)</sup>.

### E. Catalan's Appliance

It first appeared 150 years ago. Lower inclines are utilized to address the anterior crossbite in Catalan's appliance. The eruption of posterior teeth induces the opening of a bite (Figure 2E). It is used when incisors are about to erupt. The incline of 45° guides lingually erupting incisors into proper occlusions. It is worn for a maximum of three weeks, yet if worn for longer, it can cause an anterior open bite because of the posterior tooth over-eruption<sup>(26)</sup>.

### F. Elastomeric Ligature with Guard

3 M Unitek Company develops it with an external diameter of 3.1 mm (Figure 2F). It is latex free and designed to reduce the occlusal contact with the ceramic brackets in the mandible<sup>(27)</sup>. It is not readily available in many countries, and its effectiveness is not studied yet.

## 2. Posterior Bite Raisers

The mandible rotates anti-clockwise due to intruding posterior teeth and correcting an anterior open bite, decreasing the lower anterior facial height<sup>(22,23)</sup>. A posterior bite plane that extends from the first premolar posteriorly to dis-occlude anterior teeth will be beneficial for managing an anterior crossbite. Due to the vertical intrusive forces on the posterior segments, they have also been utilized to manage cases of open bites.

### Fixed Posterior Bite Raisers

#### A. Temporary Crowns Bite Raiser

Those are self-cure acrylic crowns manufactured bilaterally on molars and cemented onto teeth with glass ionomer

cement (Figure 3A). They assist in correct anterior crossbite by acting as temporary bite raisers. They benefit from being less bulky, resulting in less speech defects, and they are worn all the time<sup>(28)</sup>. It is crucial to maintain good occlusal contact bilaterally.

In orthodontics, stainless-steel crowns for bite-jumping, space maintaining, and bite-opening treatment have increased<sup>(9)</sup>. Ormco designed its crowns with orthodontists in mind, and they offer various benefits:

1. Gingival contouring and height reduction remove or lessen the requirement for trimming.
2. Broad with a somewhat flat occlusal surface accommodates the anatomy of the tooth crown without requiring occlusal surface reduction.
3. Flatter inter-proximal walls occupy less arch space than the more rounded, bulbous crowns, standard in pediatric dentistry.

Steel crowns are rarely used nowadays since they are expensive and require different-sized stocks, and the availability of resin and metal turbos with simple application techniques encourages orthodontists to avoid crowns.

### B. Nano Bite Plane

It is a fixed type consisting of a molar band with a well-adapted zig-zag shaped 0.019×0.025 inch archwire that soldered at just two points to provide sufficient bond strength and minimize the bulkiness of the appliance, leaving the buccal side of the band free for other attachments if needed. The wireframe is covered by acrylic and adjusted to the required height (Figure 3B).

It is considered simple, reliable, and effective in either arch, especially useful in uncooperative patients and high-angle cases. To prevent overeruption of adjacent posterior teeth in vertically growing patients, the bite plane should be modified to include more of the posterior teeth if it must be used for more than four weeks. Both adults and adolescents tolerate the bite plane well, usually requiring only a few days to adapt to speech and

chewing<sup>(29)</sup>. This method needs laboratory work for fabrication, just like the temporary crowns.

### C. Posterior Resin Turbo

In the cases of the average angle, the posterior resin turbos are recommended. Posterior resin turbos are commonly put on the mandibular first molars' supporting cusps. In preadolescent patients, they could be placed on the mandibular second deciduous molars<sup>(11)</sup>. For ease of manufacture and better isolation, a few clinicians prefer that they become placed on premolars or maxillary molars. In general, posterior turbos are less successful at offering clearance for lower anterior brackets, and in low-angle patients, they could require excessive thickness (Figure 3C). For added bracket retention, they could be extended over the bracket pad. Built-up composite onlays on the lower back teeth that provide deep intercuspation, according to Fiorelli and Melson<sup>(30)</sup>, can avoid anchorage loss.

Abbas and El-Bokle<sup>(31)</sup> and El-Bokle<sup>(32)</sup> used a functional bite turbo that functions similarly to a bonded Twin Block appliance (Figure 3D). Also, they could be used on the premolars to help with disarticulation in Class II patients, as occluding premolars slide along beveled surfaces, disarticulating and repositioning the mandible. Together with the full-time light short Class II elastics, such bonded inclined bite raisers are employed (i.e., bonded inclined bite raisers elastics [B.I.B.R.E.]). Furthermore, using bite raisers caused disocclusion, which aided sagittal correction by reducing the impact of intercuspation, which might obstruct dentoalveolar correction or the forward mandibular growth. In contrast to most fixed functional appliances, which need at least six months of alignment and leveling before heavier archwires are installed, the B.I.B.R.E. could be used right at the start of appliance treatment with mild leveling archwires. When the patient is nearing the conclusion of a growth spurt, no time is lost.

The B.I.B.R.E. additionally offers a flexible overbite correcting function. The raisers are positioned posteriorly on molars in open bite cases to cause posterior intrusion and anti-clockwise mandibular rotation. They could be moved forward on the first premolars in low-angle situations to improve lower facial height and bite opening. The effect of B.I.B.R.E. must be studied in a randomized clinical trial as the presented cases are individual, and the skeletal and dental effects cannot be generalized to all cases.

The same procedure could be used in aligner patients by adding unfilled rectangular attachments to aligners' occlusal surfaces<sup>(11)</sup>.

Prasad and Sivakumar<sup>(33)</sup> assessed the effect of light-cured orthodontic composite (Blu Bite) used as a bite raiser on the periodontium of the lower molars and found minor but significant changes in the periodontium with increasing mean probing depth and pain score.

#### D. Güray Bite Raiser

Güray bite raiser can be defined as a temporary bite raiser prefabricated. It is designed to be put into headgear tubes and adapted over molars' occlusal surfaces (Figure 3E). It is offered in two sizes for adults and children and is secured by ligature wire or elastomer<sup>(10,34)</sup>.

This type has the following advantages:

1. It may be readily and swiftly placed or withdrawn without causing pain to the patient or requiring the use of special devices.
2. The patient's bite relation could be checked as often as needed by removing the ligature and hinging the device out of occlusion.
3. No laboratory processes are needed.
4. Patient acceptance was on par with that of previous bite-opening devices.
5. The stainless-steel appliance is adjustable and can be used with occlusal or gingivally placed headpiece tubes.

The following drawbacks were reported:

1. It could not be possible to install headgear and auxiliary wires simultaneously.
2. It must also be avoided in situations in which anterior bite planes are needed.
3. Long-term wear may cause molar intrusion, which can be reversed with a suitable wire bending technique.

#### E. Bonded Posterior Bite Plate with Expansion Screw

In hyperdivergent patients, bonded Hyrax has been frequently utilized to address maxillary crossbite. Bonded posterior bite plane disoccludes posteriors for the unhindered expansions and, if left for lengthy periods, will lead to molar intrusion (Figure 3F). The bite should be raised 3-4mm beyond freeway space for best effects. A convenient shifting of the mandible because of bilateral maxillary constriction typically results in a unilateral cross-bite. A posterior bite plane maxillary expansion device might free the mandible from its laterally locked position and improve maxillary expansions. The posterior bite plane is also beneficial in bilateral posterior crossbite<sup>(22,23)</sup>.

#### F. Spring Loaded Posterior Bite Blocks

Woodside and Linder-Aronson described the spring-loaded block<sup>(35)</sup>. Those bite blocks are constructed up of helical springs composed of 0.9mm high strength wires of stainless steel, the ends of which are implanted into acrylic blocks, and they cover the occlusal surface of posterior teeth. The bite blocks are bilaterally connected with 1mm stainless steel wires or acrylic plates that could be extended up to the cingulum or cap incisors to prevent over-eruption. Forces are delivered via activating the helices (Figure 3G). They are periodically activated, providing additional force within the neuromuscular system and the masticatory muscles' forces. It has been considered that this same appliance may work as a habit-breaking appliance due to its quirky design. The patient should use active force to seal the

mouth with that equipment, which serves as distraction treatment<sup>(36)</sup>.

### **G. Rapid Molar Intruder (R.M.I.)**

Carano employed a rapid molar intruder for treating non-compliant patients with open bites. It is made up of elastic modules and coil springs that aid active molar intrusion. With bands, the device has been secured to mandibular and maxillary molars<sup>(37)</sup>.

An 800g force is applied to teeth during occlusion, decreasing to 450g by the first weekend and 250g by the 2<sup>nd</sup> weekend. One disadvantage of R.M.I. treatment is buccal crown tipping since the force's line of action is lateral to the molars' center of resistance. Transpalatal and lingual arches could help to counteract this. Rather than molar bands, the R.M.I. could be adapted to use bite blocks. Tubes might be introduced into the R.M.I. and added to the blocks' buccal side. This has the extra benefit of distributing R.M.I. force throughout the block rather than concentrating it on the molars<sup>(37,38)</sup>.

### **H. Magnetic Bite Blocks**

Dellinger was the first to treat an open bite using magnets. The appliance was dubbed the active vertical corrector by him<sup>(39)</sup>. To intrude teeth, repelling magnets are used in opposing arches (Figure 3H). Magnets made of Samarium Cobalt are employed. Because this represents reactive material, it must be sealed in the oral condition because saliva could serve as an electrolyte. Magnets might be utilized after being embedded in acrylic, preventing leakage and corrosion of possibly hazardous materials. Later, MAD IV device was presented this device employed Neodymium Iron Boron magnets coated with stainless steel (three times stronger than Samarium-Cobalt magnets). This device delivers both vertical and lateral shearing forces.

### **I. Implant Supported Bite Blocks**

Using posterior bite blocks and skeletal anchorage to allow posterior tooth intrusion is a reasonably novel procedure. Compounds

effects of the posterior bite blocks and permits enmasse intrusion with a sufficient level of stability. It is a very invasive approach that necessitates incisions for placement implantation—in non-growing individuals, using coil springs or elastics in combination with T.A.D. The transpalatal arch controls buccal flaring. The acrylic blocks have hooks embedded to make applying the elastics easier<sup>(40)</sup>.

### **J. Bonded Mandibular Posterior Bite Plane**

It is made up of a 1mm stainless steel wire that is adapted to the lingual surface of the lower anterior teeth (above the cingulum) and extends from the lower first premolar to that on the other side and self-cure acrylic extending on the mandibular posterior teeth from the first premolar to the second molar on the two sides for forming the posterior bite plane (Figure 3I). The acrylic must be applied to half of the buccal and lingual surfaces of posterior teeth on the two sides, avoiding the gingival margins<sup>(41)</sup>.

### **K. Two Separate Posterior Bite Plates**

It was made of two acrylic bite blocks with stainless steel tubes (16-gauge needle) (Figure 3J). Ligature wire extended throughout the tube with one end below and the other above the contact aiding in fixation of the block in addition to glass ionomer cement<sup>(42)</sup>. This method was convenient and reliable, mainly because it prevents the bite block from loosening before the patient's visit and keeps the bite open as required. Furthermore, since the bite block is secured with ligature/brass wire, it could be supplied unilaterally without risk of swallowing. The appliance is also proven to have excellent patient compliance, but it seems complicated.

### Removable Posterior Bite Raiser

#### **A. Hawley Posterior Bite Plane**

It can be described as a removable posterior bite plate that covers the occlusal surface of the back teeth and hinges mandible open 3-4mm beyond the resting position



(Figure 4). They have the benefit of exerting fundamentally vertical forces, resulting in a reduction in posterior dentoalveolar height, relative anterior teeth extrusion, and forward and upward rotation of the mandible—this aids in the correction of openbite. An inclined plane or ramp could be included in desired tooth movement direction in cases of scissor bite. It is utilized in removable appliance therapy for crossbite correction alongside the Z-spring or mid-palatal jack screw<sup>(22,23)</sup>.

#### Semi-Fixed Posterior Bite Raiser

It consists of two pieces of posterior bite blocks with zig-zag loops of 2 mm width made of 0.017×0.025-inch stainless steel wire wrapped in acrylic that extended on the two sides from the first premolars to the first molars. With a 90° bend (bends could be changed according to necessity) from the occlusal surface and another 90° bend at the level of the slot to be inserted, the distal end of the wire was inserted in either slot auxiliary or main (Figure 5). According to convenience, the wire might also be placed from the mesial side<sup>(43)</sup>.

#### **Advantages of Bite Turbos<sup>(3)</sup>**

1. Hygienic.
2. Required less chairside time.
3. Relatively comfortable as it results in minimizing the bulkiness.
4. Decrease the interferences with the speech.
5. Less intrusive on tongue space in comparison with traditional acrylic plates.

#### **Disadvantages of Bite Turbos<sup>(3)</sup>**

1. Anterior teeth mobility and loss of vitality.
2. It may cause intrusion of posterior teeth leading to posterior open bite.
3. Wearing of the resin materials.
4. Breakage or debonding.

#### **Disadvantages of Bonded Bite Plane<sup>(3)</sup>**

1. Can cause soft-tissue irritation.
2. Contraindicated in mixed dentition with exfoliating deciduous teeth and the permanent teeth in various stages of eruption.
3. Not indicated in patients with a very short clinical crown height due to frequent dislodgement.
4. Not indicated in patients with poor oral hygiene.
5. Prevents early tooth movement (especially the mandibular one) as it covers posterior teeth' occlusal surfaces.
6. Affect the speech.
7. Difficulty in eating.

#### **Disadvantages of Removable Bite Plane<sup>(3)</sup>**

1. Largely depended on patient cooperation
2. Need recurrent adjustments for accounting for orthodontic tooth movements.
3. Easily broken or lost and often swallowed by the patient.
4. They could also create areas for plaque accumulation causing inadequate oral hygiene and high risks of dental decay.
5. Over-extended bite plates will cause gagging.
6. It may cause oral ulcers due to the sharp ends.
7. Affect speech.
8. Candidal infection.

#### **Material Choices**

According to the materials from which they are fabricated, the types of bite raisers are shown in Figure 6. Numerous materials were suggested for the bite raisers, including acrylic resin, band cement, acrylic gels, lingual retainer adhesives, and bracket adhesives.

Each has advantages and disadvantages related to its color, placement and removal techniques, and glass filler content, as shown in Table 1<sup>(11,44,45)</sup>.

An attempt to test some physical and mechanical characteristics of the injectable polymer materials (namely M10 and Acrilato) acting as a substitute for cold cure acrylic was performed, and the findings indicated that the good properties of these materials make them proper alternatives to the Orthocryl. However, the main problem is the availability and cost of required softening devices in the dental labs<sup>(46)</sup>.

On the other hand, two studies have been conducted to test the shear bond strength and the wear resistance of different adhesive materials used as a temporary bite raiser. In the first study, three types of adhesive were tested, namely Transbond XT, Light Cure Adhesive, Transbond Plus, Light Cure Band Adhesive, and Transbond Supreme LV, Low Viscosity Light Cure Adhesive from 3M Unitek, and the findings showed that there had not been any statistically significant differences amongst their bond strength values. All three materials may be utilized as temporary bite openers<sup>(47)</sup>.

In the second study, the wear resistance of Transbond LR, Transbond Plus from 3M, and Triadgel from Dentsply were tested, and the findings showed that all of the bite turbo materials wore more than the natural enamel; however, it resulted in equal or less wear to the opposing enamel compared to the tooth-tooth contact. Bite turbo material that has been utilized can be chosen according to the preference for longevity<sup>(48)</sup>.

Further studies are needed to assess the shear bond strength of metal and tooth-colored bite raisers and evaluate the wearing effects of metal and tooth-colored bite raisers compared to resin turbos. In addition, Fermit material has never been tested regarding its wearing, shear strength, and effect on the enamel surface of the opposing teeth.

### Application of Bite Raisers

Generally, bite planes made from acrylic are fabricated in the laboratory. Metal and tooth-colored bite turbos are bonded directly on the palatal surface of the maxillary central

incisors. On the other hand, resin bite turbos can be bonded on the teeth surface directly or by using special mini-molds (especially in the anterior region). A customized tray for indirect bonding has been used for more simplicity and accuracy<sup>(19)</sup>.

Alsheikho and Jomah<sup>(49)</sup> described a simple, less expensive, and fast method of fabricating mini-molds with their holders utilizing the insulin injection syringe, bond brush holder, disc separator, acrylic tooth, and at home silicone gun so that the desired length can be cut and used as a substitute for the ready-made mini-mold.

### Biomechanics

Biomechanics aid the clinician in visualizing the expected tipping direction and planning the right length and thickness of the bite plane. Bite raisers have different mechanics when utilized with fixed orthodontic treatment, which was briefly explained<sup>(3)</sup>:

#### **Effects of the bite plane upon the inclination of the incisors in the case where the anterior bite blocks have been placed in the mouth of the patient**

a) in the case where mandibular and maxillary incisors are practically upright, intrusive forces pass somewhat labial to the mandibular incisor's center of resistance, whereas the intrusive forces pass through the center of resistance for the maxillary incisor. As a result, there will be a proclination of the mandibular incisors.

b) in a case where maxillary incisors are upright and the lower incisors are proclined, intrusive forces lingually pass to the maxillary incisors' center of resistance and labially to the mandibular incisors' center of resistance, resulting in more proclination of the mandibular incisors and retroclination of the maxillary incisors.

c) in the case where the mandibular and the maxillary incisors have been proclined, intrusive forces will labially pass to the center of resistance of the mandibular incisors and the maxillary incisor, thereby

resulting in the proclination of the two segments (Figure 7).

### **Effects of the bite plane upon molar inclination in the case where posterior bite blocks have been placed in the mouth of the patient**

a) when a force is applied on the molar's distal cusp, located far from its center of resistance. Therefore, the distal tipping of this molar will occur.

b) in a case where the molar has been already mesially tilted, the force will be extremely distal to its resistance center; hence a significant moment will not be generated for correcting the molar: which is why the bite turbo is extended farther distally for producing intrusive forces further away from the center of resistance, which leads to the uprighting of the mesially tipped molar (Figure 8).

### **Effects of Bite Raisers on the Masticatory Functions and Electromyography**

The effect of bite raisers on the masticatory functions and electromyography (E.M.G.) activity have been studied in different researches. Pativetpinyo et al. <sup>(50)</sup> studied the immediate effects of light-cured orthodontic band cement on the superficial masseter and anterior temporalis E.M.G. activity in healthy adults and found an altered neuromuscular behavior during clenching and chewing of these muscles. Sankaranarayanan and Subramanian <sup>(51)</sup> reached the same conclusions using the light cured orthodontic band cement and the traditional acrylic bite plane.

Changsiripuna and Pativetpinyo <sup>(52)</sup> evaluated the effect of light-cured orthodontic band cement on the masticatory function and found it will be immediately reduced, both objectively and subjectively, yet it did not perceive by the individuals.

### **Effects of Bite Raisers on the Condylar Position**

Only one study by Herrera-Guardiola et al. <sup>(53)</sup> assessed the changes in the condylar

position that occur three months after treatment with posterior bite turbos. The findings indicated non-significant changes in condylar position during this period with well-tolerance by the patients.

### **Factors Influencing the Choice of Bite Raisers' Location**

There are several factors affecting the choice of the bite raisers <sup>(3,33)</sup>:

#### **1. Facial type or the direction of mandibular growth**

The dolichocephalic type tends to have a backward mandibular rotation that needs molar intrusion, so a posterior bite raiser is required to intrude the molars and reduce the open bite. On the other hand, for the brachycephalic type, an anterior bite raiser is required to open the bite posteriorly, allowing extrusion of the premolars and molars and allowing the anterior teeth intrusion. For the mesocephalic, it can be placed on the premolars near the center of jaw rotation.

#### **2. The Sagittal Jaw Relation**

In the case of class II relation, placing an inclined bite raiser on the premolars to advance the mandible forward, i.e., as the action of twin block, is a good option. On the other hand, in class III, it can be placed on the lower incisors either to open the bite or to treat the negative overjet as the functional bite turbos can procline the upper incisors.

#### **3. The amount of Overjet**

With an increased overjet, an inclined bite raiser can be placed on the premolars to reduce the amount of overjet. In deep bite cases, the best location of the bite raiser is the maxillary central incisors, but if the case is associated with increased overjet, it can be placed on the canine first, and after marked overjet reduction, it can be placed on the central incisors.

#### 4. Presence of Crossbite

With arch constriction and the development of crossbite and long face, the maxillary arch can be expanded with bonded Hyrax.

#### Delivery of Removable Bite Raisers

At the time of removable bite raiser delivery, several things should be checked<sup>(22,23)</sup>:

1. Before placing the removable appliance, the physician must inspect the appliance for any minute pimples caused by blowholes that can irritate the mucosa, and the free edges must be smooth and rounded.
2. While fitting the item in the mouth, the base plate might need to be trimmed.
3. Show the patient how to remove and insert the appliance in a mirror.
4. Check the bite plane for occlusal wear or breakage caused by masticatory forces.
5. When an anterior crossbite needs to be corrected, the clearance between the maxillary and mandibular anterior teeth is evaluated to ensure enough space for the tooth in crossbite to jump the bite.
6. To ensure an equal bite, bite adjustment should be achieved with articulating paper.

#### Instructions to the Patient

Any removable appliance will be successful if the patient attentively follows the guidelines<sup>(22,23)</sup>:

1. The parent and patient must receive enough verbal counseling and a written list of "don'ts and do's".
2. The patient must be told to wear the appliance 24 hours a day and take it out to brush their teeth and throughout contact sports and swimming.
3. Strict oral hygiene should be enforced to avoid fungal infection or enamel decalcification.

4. The patient must be taught to clean the appliance with water and soap after use. Cleaning must be done with caution to avoid bending or distorting any components.
5. Because of the encroachment of tongue space, the patient may have difficulty speaking. In about a week, things will be back to normal.
6. Because the upper teeth occlude on the acrylic platform of the mandibular bite plane, eating could be complicated for some days following cementation. With time, the patient will become accustomed to it.
7. In pain or appliance damage, the patient should be told to come to the clinic immediately.
8. Patients must be told that leaving the appliance out of their mouth for an extended time increases the chances of it being distorted or damaged and bracket debonding.
9. When the appliance is not in use, it must also be kept away from children and pets.

#### Discussion

In general, bite raisers are essential for treatment with the Damon system and conventional labial and lingual orthodontic appliances. The selection of the types, materials, and locations are influenced by the experience, availability of the materials, and the case itself<sup>(11)</sup>.

Some of the simple cases of an anterior crossbite can be corrected easily within three months using functional anterior bite turbos placed on the mandibular incisors<sup>(20)</sup>. This can be considered part of interceptive orthodontics to prevent further problems associated with an anterior crossbite.

One of the primary treatment strategies with the Damon system is using light intermaxillary elastics from day one in conjunction with bite turbos. The role of these turbos is to disarticulate the teeth allowing easy and rapid movement and

enhancing the effect of the early use of elastics and the broad archwire form<sup>(54)</sup>.

Developing a new method for correcting the sagittal jaw relation using the bonded inclined bite raisers and elastics (B.I.B.R.E.) is considered a treatment of choice as these inclined bite raisers enforce the mandible to be in a forward position so that the correction of the sagittal discrepancy will be treated from day one without the need for completing the alignment stage<sup>(31)</sup>.

The choice of the materials used to fabricate the bite raiser other than the acrylic is merely the orthodontist's preference as there are metal and clear bite raisers that are ready-made and bondable, just like the brackets. On the other hand, posterior bite turbos are fabricated from different adhesive materials like flowable composite, band cement, and acrylic gel, and here the availability and the applicability of the material is the major factor. Light cure band cements with different colors can be bonded and removed easily at a low cost.

Despite various forms of bite raisers, there is no evidence to distinguish the best type. This can be attributed to the lack of R.C.T.s about this subject because a standardized study with different parameters might be difficult to conduct on many patients as the cases might differ in the three planes of space, age, and state T.M.J. so on.

Long-term studies on large sample sizes are required to examine the effect of different bite raisers on the condylar position, T.M.J., periodontal health of the teeth, enamel structures, masticatory functions, and rotation of the mandible, and the effect of the sagittal jaw relationship.

### Conclusions

From this review, the authors concluded that a disarticulation is a valuable tool in orthodontic therapy, either enhancing the early bonding of lower anterior brackets or correcting deep bite and cross bite cases. Many means of bite raising have been explained; each has advantages and disadvantages, but the choice depends on the

case itself; patient's cooperation and a good understanding of their cost, action, methods of fabrication, and uses are crucial for the avoidance of iatrogenic effect.

Fixed bite turbos are preferred over the removable plane as patients' cooperation is not required; moreover, the problems associated with removable ones like losing, breakage, and not wearing the appliance are minimized.

### Conflicts of Interest

The authors declare that they have no conflicts of interest.

### References

1. Daskalogiannakis J. Glossary of orthodontic terms. Berlin: Quintessence Publishing Co., 2000.
2. Roy AS, Singh GK, Tandon P, De N. An interim bite raiser. *Int J Orthod Milwaukee* 2013; 24(2): 63-64.
3. Singh G, Gupta H, Rathi A, et al. The use of bite raisers in orthodontic treatment –A review of literature. *Acta Sci Dent Sci* 2021; 5(4): 219-228.
4. Weinberger BW. Orthodontics; a historical review of its origin and evolution, including an extensive bibliography of orthodontic literature up to the time of specialization. St. Louis: The C.V. Mosby; 1926.
5. Kingsley NW. Adenoid growths, mouth breathing and thumb sucking in their relation to deformities of the jaws and irregular teeth. *Dental Cosmos* 1892; 34(1): 16-22.
6. Angle EH. Treatment of malocclusion of teeth. 7<sup>th</sup> ed. Philadelphia: S.S White Dental manufacturing Co.; 1907.
7. Suggett AH. Some uses of the inclined plane. *Int J Orthod* 1915; 1(5): 243-246.
8. Grieve GW. Buccal inclined planes, in conjunction with the pin appliance, for stimulation of growth of the

- mandible (clinic). *Int J Orthod Oral Surg Radiogr* 1927; 13(10): 883-885.
9. Mayes JH. Bite turbos: New levels of bite-opening acceleration. *Clin Impression* 1997; 6(1):15-17.
  10. Güray E. Temporary bite raiser. *J Clin Orthod* 1999; 33(4): 206-208.
  11. Kravitz N, Jorgensen G, Frey S, Cope J. Resin bite turbos. *J Clin Orthod* 2018; 52(9): 456-461.
  12. Fine HA. A fixed labial/lingual technique for rapid bite opening. *J Clin Orthod* 1991; 25(10): 606-607.
  13. Al-Zoubi EM, Al-Nimri KS. A comparative study between the effect of reverse curve of Spee archwires and anterior bite turbos in the treatment of deep overbite cases: A randomized clinical trial. *Angle Orthod* 2022; 92(1): 36-44.
  14. Orthotechnology product catalogue 2022.  
<https://www.orthotechnology.com> > 2022/02.
  15. Speed Dental product catalogue. <https://www.dentalspeed.com/catalogos/catalogo-de-productos>, 2020.
  16. Voudouris JC, Gaveglia V, Poulos JJ. BiTurbo2 (BT2) system for rapid deep overbite correction. *DW Journal*.  
<https://dentalworld.hu/biturbo2-bt2-system-for-rapid-deep-overbite-correction/2022>.
  17. Prakash A, Chaturvedi N, Balani R, Bharti C. Button bite turbo. *J Indian Orthod Soc* 2018; 52(3): 217-218.
  18. Philippe J. Treatment of deep bite with bonded biteplanes. *J Clin Orthod* 1996; 30(7): 396-400.
  19. Tong H, Lee R, Weissheimer A. Indirect bonding trays with bite turbo and orthodontic auxiliary integration. U.S. Patent No. 2020/0275996 A1. Swift Health Systems Inc., 2020.
  20. Kravitz N. Interceptive orthodontics with resin turbos for pseudo-class III malocclusions. *Case Reports in Dentistry* 2019; 2019: Article ID 1909063.
  21. Pratiwi D, Purwanegara MK. Deep bite correction with an anterior bite plate in a growing patient. *Sci Dent J* 2020; 4(3): 129-133.
  22. Singh G. Textbook of orthodontics. 3<sup>rd</sup>ed. New Delhi: Jaypee Hights Medical Pub Inc; 2015.
  23. Phulari BS. Orthodontics Principles and Practice. 2<sup>nd</sup>ed. New Delhi: Jaypee Brothers Medical Publishers (P) Ltd.; 2017.
  24. Sved A. Changing the occlusal level and a new method of retention. *Am J Orthod* 1944; 30(10): 527-535.
  25. Emami MS, Jamilian A, Showkatbakhsh A. The effect of anterior inclined plane treatment on the dentoskeletal of Class II division 1 patients. *J Indian SocPedo Preventive Dent* 2007; 25(3): 130-132.
  26. Tiwari N, Tiwari S, Sharma D. Management of anterior cross bite in mixed dentition using Catlan's appliance. *Acta Sci Dent Sci* 2020; 4(2): 106-109.
  27. Elastomeric ligature with guard. 3M Unitek.  
<https://www.orthodepot.de/ORTHO--OrthoDepot/Elastomers/Elastic-ligatures/Elastomeric-Ligature-With-Guard-Ligature--3M-Unitek-.html?language=en>
  28. Vibhute PJ, Srivastava S, Hazarey PV. Temporary bite-raising crowns. *J Clin Orthod* 2006; 40(4): 224-230.
  29. Prasad V, Sharma VP, Tandon P, Singh GP. A New fixed biteplane. *J Clin Orthod* 2008; 42(11): 661-662.
  30. Fiorelli G, Melsen B. Occlusion management in orthodontic anchorage control. *J Clin Orthod* 2013; 47(3): 188-197.
  31. El-Bokle D, Abbas NH. A novel method for the treatment of Class II malocclusion. *Am J Orthod*

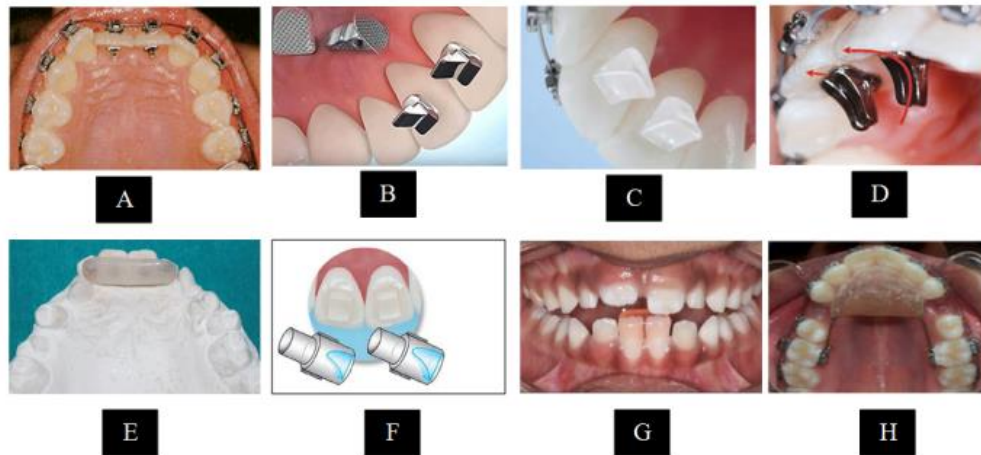
- Dentofacial Orthop 2020; 158(4): 599-611
32. El-Bokle D. Posterior functional bite turbos for sagittal correction. *J Clin Orthod* 2021; 55(7): 435-436.
  33. Prasad AS, Sivakumar A. Effect of posterior bite raiser on periodontium of lower molars in orthodontic patients. *J Evol Med Dent Sci* 2021; 10(23): 1756.
  34. Gokalp H, Uslu O. Treatment of class III anterior crossbite using Güray bite raisers. *J Clin Orthod* 2008; 42(5): 297-300.
  35. Woodside DG, Linder-Aronson S. Progressive increase in lower anterior face height and the use of posterior occlusal bite-block in its management, In: Graber, L. W. (ed.), *Orthodontics: State of the Art, Essence of the Science*. St Louis: CV Mosby Co; 1986. pp. 200-221.
  36. Doshi UH, Bhad WA. Spring-loaded bite-blocks for early correction of skeletal open bite associated with thumb sucking. *Am J Orthod Dentofacial Orthop* 2011; 140(1): 115-120.
  37. Carano A, Machata W, Siciliani G. Noncompliant treatment of skeletal open bite. *Am J Orthod Dentofacial Orthop* 2005; 128(6): 781-786.
  38. Cinsar A, Algha AR, Akyalçin S. Skeletal open bite correction with rapid molar intruder appliance in growing individuals. *Angle Orthod* 2007; 77(4): 632-639.
  39. Dellinger EL. A clinical assessment of the active vertical corrector-A nonsurgical alternative for skeletal open bite treatment. *Am J Orthod* 1986; 89(5): 428-436.
  40. Doshi UH, Bhad WA. Implant-supported bite blocks for open bite correction in adults. *J Indian Orthod Soc* 2012; 46(2): 86-92.
  41. Sumathi FA. Bonded mandibular posterior bite plane: Fabrication, insertion and uses. *Tanazaia Dent J* 2012; 17(2): 56-60.
  42. Ahmad N, Ansari A, Gera A, Kaur G. A new method to retain the posterior bite blocks for anterior crossbite correction. *J Indian Orthod Soc* 2014; 48(2): 139-140.
  43. Sharma VK, Yadav K, Shastri D, Chaturvedi TP. An efficient semi-fixed bite raiser. *J Indian Orthod Soc* 2016; 50(3): 194-195.
  44. Zafar MS. Prosthodontic applications of Polymethyl Methacrylate (P.M.M.A.): An Update. *Polymers* 2020; 12: 2299.
  45. Weissheimer A, Lee R, Tong H, Pham J. Flexible bite turbos for lingual appliances. *J Clin Orthod* 2020; 54(10): 631-632.
  46. Albo Hassan AF, Jameel A, Nahidh M, Hamid D. Evaluation of some mechanical and physical properties of different types of injectable polymer materials used as a base for removable orthodontic appliances. *J Stoma* 2019; 72(5): 215-221.
  47. Kılınç DD, Sayar G. Comparison of shear bond strength of three different adhesives used as temporary bite raiser in daily orthodontic practice. *Int Orthod* 2018; 16(3): 440-449.
  48. Feagin K, Kwon SJ, Farheen F. In vitro comparison of wear of three orthodontic bite materials and opposing enamel. *Int Orthod* 2021; 19(3): 494-499.
  49. Alsheikho HO, Jomah D. A simple technique to fabricate bite turbos. *J Indian Orthod Soc* 2021; 55(3): 331-335.
  50. Pativetpinyo D, Suprongsinchai W, Changsiripun C. Immediate effects of temporary bite-raising with light-cured orthodontic band cement on the electromyographic response of masticatory muscles. *J Appl Oral Sci* 2018; 26: e20170214.
  51. Sankaranarayanan RR, Subramanian AK. Effect of temporary bite raising

- with light cured orthodontic band cement and acrylic bite plane on the electromyographic response of masticatory muscles. *Ann Dent Oral Health*. 2021; 4(1): 1036
52. Changsiripun C, Pativetpinyo D. Masticatory function after bite-raising with light-cured orthodontic band cement in healthy adults. *Angle Orthod* 2020; 90(2): 263–268.
53. Herrera-Guardiola S, Puerta-Salazar GE, Martínez Cajas CH. Condylar position changes after three months of treatment with posterior bite turbo. *Rev Fac Odontol Univ Antioq* 2020; 32(1): 18-25.
54. Pitts T, Duncan B. I.L.S.E. Immediate, Light, Short, Elastics with Disarticulation. Protocol 2017; 6: 8-16.

**Table 1: Different materials used in fabricating bite raisers** (11,44,45)

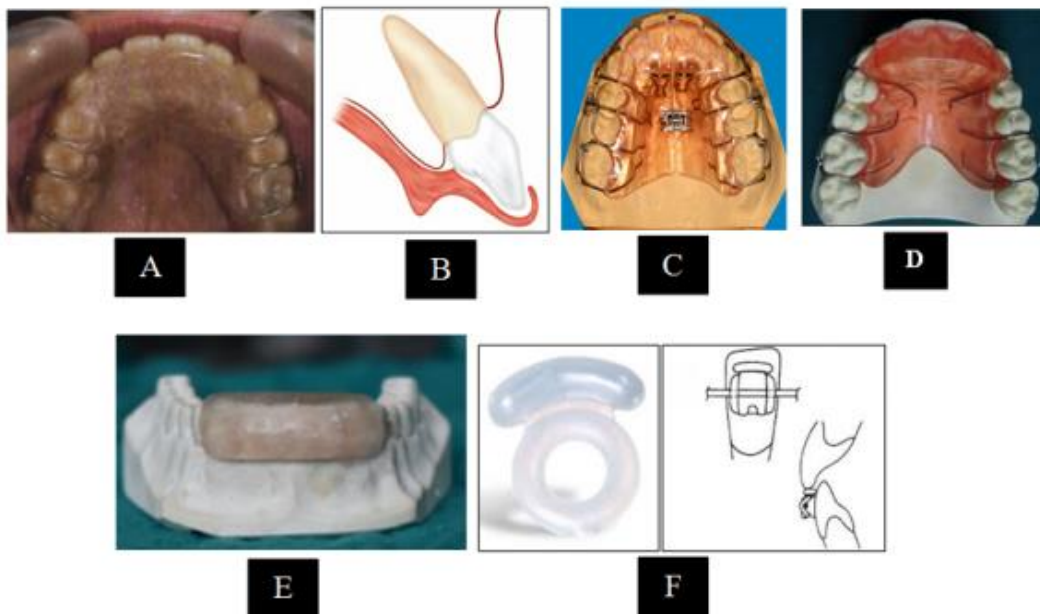
| Products                         | Original Purposes  | Type                                 | Advantages  | Disadvantages  |
|----------------------------------|--|--------------------------------------|---|--|
| Vulcanite                        | Denture base material, bite plate  | Soft rubber sulfur compound          | Cost-effective, dimensionally stable, comfortable, low density, lightweight, and is easily fabricated   | Poor esthetics   |
| Acrylic                          | Fabricating custom trays and provisional partial dentures, denture repair, and bite plates | Cold-cured P.M.M.A.                  | Better dimensional stability and adaptation resulting in minor polymerization shrinkage   | Low strength and hardness due to poor polymerization, monomer leaching, inferior mechanical properties, and poor color stability and discoloration due to the oxidization of the amine initiators with time. |
| Triad Gel                        | Bite plates, cast modification   | Acrylic gel                          | Soft, light color   | Polymerization shrinkage, hyperemia  |
| Ultra Band-Lok                   | Band cement  | Compomer paste                       | Bonds to metal, distinct color  | Casts a blue shade   |
| TruLock Light Cure Band Adhesive | Band cement  | Compomer paste                       | Bonds to metal, distinct color, fluoride-releasing  | Casts a blue shade   |
| Ketac                            | Band cement, permanent restorations  | Glass ionomer cement                 | Moisture insensitive, fluoride-releasing  | Difficult to remove  |
| Blugloo, Greengloo               | Bracket adhesive   | Resin paste                          | Color change  | Potential for wear   |
| Transbond LR                     | Lingual retainer adhesive  | Resin paste                          | Bond strength   | Potential for wear   |
| Flow Tain                        | Lingual retainer adhesive  | Flowable resin                       | Easy application  | Potential for wear   |
| Twinky Star                      | Pediatric restorations   | Compomer paste                       | Easy application, distinct color  | Potential for wear   |
| Fermit                           | Temporary inlay restorations   | Composite resin with high elasticity | Easy application and removal, remain flexible after curing, so it is accepted by patients, esthetic, compatible with both lingual and labial appliances | -  |





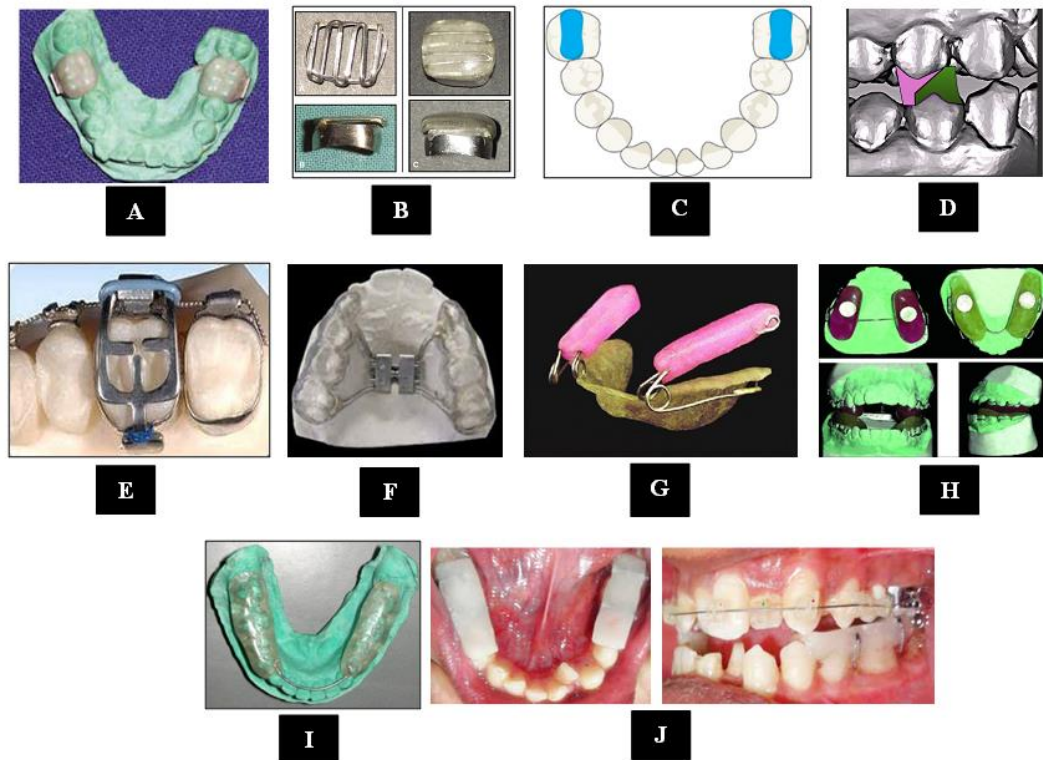
**Figure 1: Anterior fixed bite raisers**

**A: Lingual bracket as a bite raiser, B: Metal bite raiser. C: Bite builder, D: BiTurbo, E: Button bite turbo, F: Anterior resin bite turbo, G: Anterior functional resin bite turbo, H: Modified Nance Palatal Button**  
(9,11,12,14,16,17,20,21)



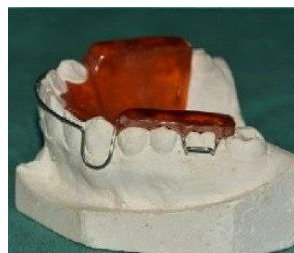**Figure 2: Anterior removable bite raisers**

**A: Hawley anterior bite plate, B: Sved plate, C: Bite plane with expansion, D: Anterior inclined bite plane, E: Catalan's appliance, F: Elastomeric ligature with guard**  
(3,22,23,25,27)



**Figure 3: Posterior fixed bite raises**

A: Temporary crowns bite raiser, B: Nano Bite Plane, C: Posterior resin turbo, D: Bonded inclined bite raisers, E: Güray bite raiser, F: Bonded posterior bite plane with expansion screw, G: Spring Loaded Posterior Bite Blocks, H: Magnetic bite blocks, I: Bonded mandibular posterior bite plane, J: Two separate posterior bite plates <sup>(10,11,29,31,42)</sup>



**Figure 4: Hawley posterior bite plane <sup>(22)</sup>**



**Figure 5: Semi-fixed posterior bite raiser <sup>(43)</sup>**

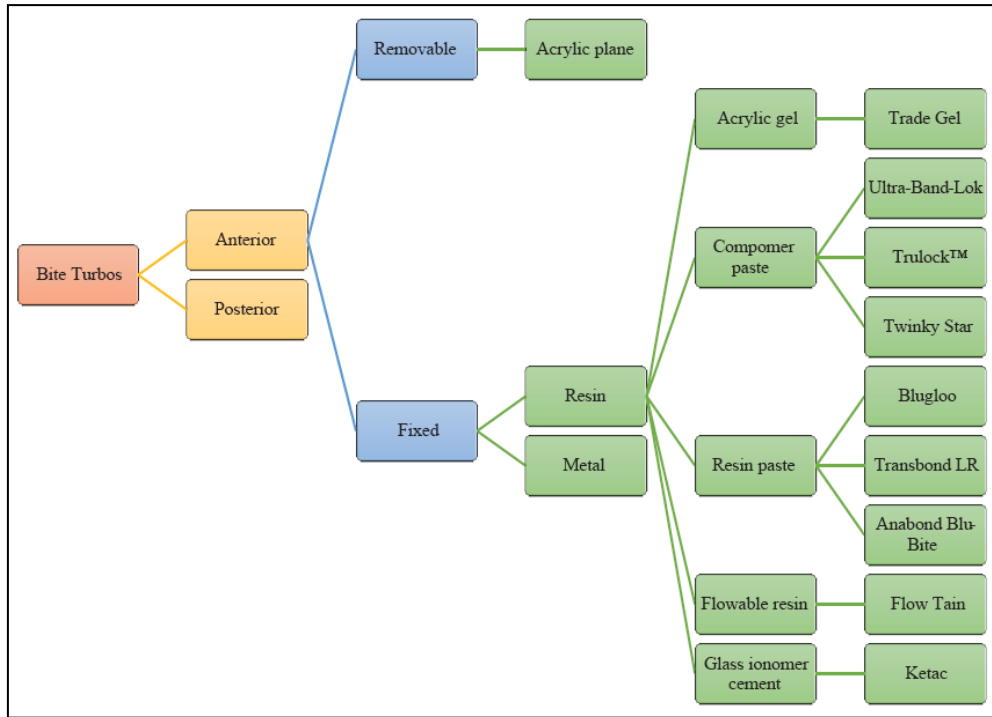


Figure 6: Types of bite raisers and their component materials <sup>(49)</sup>

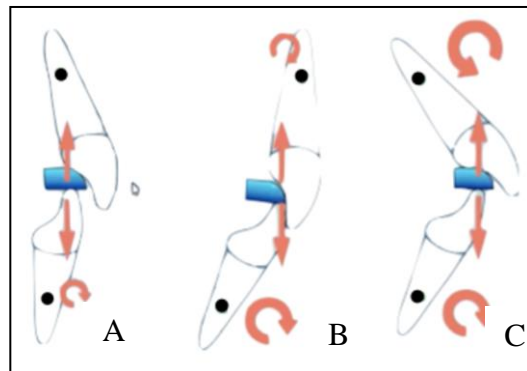


Figure 7: Effect of bite raiser on incisal inclination <sup>(3)</sup>

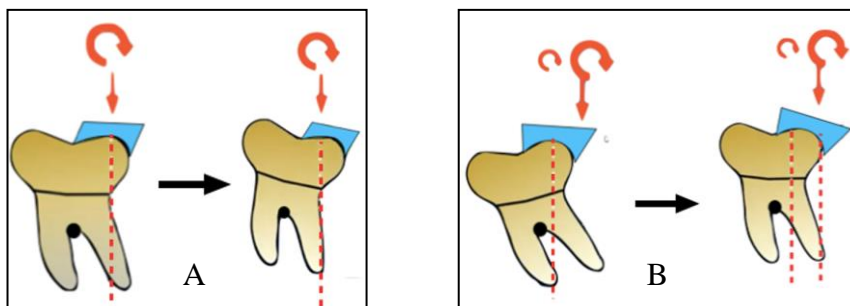


Figure 8: Effect of bite raiser on molar inclination <sup>(3)</sup>