



## A Review of the Accuracy of CBCT in the Analysis of Lingual Foramen Anatomical Variations

Nuhad A. Hassan <sup>1</sup>, Amal Raouf S. Mohammed <sup>1</sup>, and Abeer A. Aljoujou <sup>2</sup>

<sup>1</sup> *Department of Oral Medicine, College of Dentistry, Mustansiriyah University, Baghdad, Iraq*

<sup>2</sup> *Department of Oral Medicine, College of Dentistry, Damascus University, Damascus, Syria*

**Correspondence:** Nuhad A. Hassan

**Email:** [nihadalwan@uomustansiriyah.edu.iq](mailto:nihadalwan@uomustansiriyah.edu.iq)

*Received: 24 September 2023; Accepted: 23 October 2024; Published: 30 December 2024*

### Abstract

Vascular and neural components, including the lingual artery, the submental artery, and its anastomoses, in addition to mylohyoid nerve branches, all pass via the lingual foramina (LF), which are located on the lingual midline of the mandibular symphysis of the jaw. Numerous procedures, such as implantation, tori excision, and genioplasty, are performed in the anterior mandibular midline, where the LF is commonly present. Cone-beam computed tomography (CBCT), a more current scanning modality, offers 3-D images with great spatial resolution, minimal irradiation dose, and precise assessments of the anterior mandible's bone structures on a variety of planes. Bleeding, tongue elevation, and edema of the mouth floor are common surgical complications of anterior mandibular implants. This review is designed to see if the anatomical variations of the LF can be properly evaluated for implant and surgery using CBCT. Scopus, PubMed, Web of Science, Google Scholar, and the Iraq Virtual Library employ them for database searches. The identification of up to four LFs and a similarly low proportion of accessory LFs are notable.

**Keywords:** Lingual foramina, Cone beam CT, Accessory foramina, Symphysis, Mandible.

### Introduction

Nowadays, cone-beam CT (CBCT), the more recent scanning technology (Marti et al., 2016; Neves et al., 2014), provides valuable 3-dimensional radiography (3-D) and measuring software to provide images with high spatial resolution, a relative low irradiation dosage, and accurate measurements of significant bony structures of the anterior mandible (AM) on a variety of planes (Wang et al., 2020; Gaêta-Araujo et al., 2020).

Using the CBCT, the surgeon can carefully prepare for operations while keeping in mind the anatomical structures in AM. For instance, during dental implant surgery, orthognathic surgery, or osteodistraction, there is a possibility of damaging the structures in this area, resulting in severe bleeding (Liang, Frederiksen and Benson, 2004). A large hematoma in the floor of the mouth caused by this

haemorrhage may not be noticed right away, causing obstruction (Gahleitner et al., 2001; Peñarrocha-Diago et al., 2019).

The increased use of implants and grafting techniques in the front jaw bone has led to an increase in postoperative problems (Jacobs et al., 2007). Oral radiographs may reveal that the lingual foramen (LF) is well-defined (Mraiwa et al., 2003). Prior to the insertion of implants in the mandible's midline, understanding the LF is a crucial pre-surgical consideration. Numerous anatomical features, including the mandibular incisive canal (MIC) and the LF, are found in the anterior jaw (Tepper et al., 2001; Mardinger et al., 2000). The LF is in the middle of the mandible, at the same level as the mental spines, either below or above them (McDonnell, Nouri and Todd, 1994). These parts of the jaw's anatomy in the front play a big role in making the best plans for dental surgeries and preventing more problems (Liang et al., 2007).



This review is designed to see if the anatomical variations of the lingual foramen can be properly evaluated for implant and surgery using CBCT.

## Materials and methods

Scopus, PubMed, Web of Science, Google Scholar, and the Iraq Virtual Library employ them for database searches. The review covered publications from 2000 through 2022, beginning in September 2022. Throughout the search, the phrases lingual foramina, mandible, cone beam CT, accessory foramina, and symphysis were utilized. Only English-language articles were examined. Selection criteria for studies: Radiological research in three dimensions. We omitted case reports, abstracts, and panoramic studies. Frequency, diameter, number, length, position, and lateral foramen were the main evaluated factors. Researchers recorded information about anatomical variances from prior investigations.

## Results

The database search enabled the screening of 44 studies. After screening and eligibility, 27 studies were selected.

## Anatomical and clinical findings

Implant operations require in-depth familiarity with the anatomy of the small artery structures. Submental and sublingual arteries (branches of the facial and lingual arteries, respectively), as well as branches from the anastomosis between them, provide blood supply to the LF, as shown by cadaveric studies. At the hyoid bone level, the lingual artery is the third anterior and second consecutive branch of the external carotid artery (Von Arx et al., 2011; Babiuc et al., 2011). Since the primary supply of blood for the structures found in the mouth floor and tongue (Mun et al., 2016; Mei et al., 2007). The deep dorsal branches that branch out of the lingual artery provide blood to both the body and the top of the tongue. In order to reach the sublingual artery, the lingual artery must first pass through the frontal border of the hyoglossus muscle. Anatomical focus provides the groundwork for understanding the submental

artery's role as either a major vessel or a supplementary vessel in this region, which is necessary for comprehending the trends of hemorrhages arising from the perforation of the mandibular lingual cortical during implant surgery. A potentially life-threatening bleeding might be caused by mechanical damage to the arterial plexus's branch vessels (Isaacson, 2004).

## Radiographical considerations

The CBCT diagnostic is critical for surgical planning (Longoni et al., 2007; Loukas et al., 2008; Makris et al., 2010). This advancing technology's expanded diagnostic capabilities provide the physician with the skills essential to minimize potential challenges and promote the clinician's trust and predictability in implant dentistry (Stuart, 2015; Sanchez-Perez et al., 2018).

Babiuc et al. (Babiuc, 2011) evaluated the CBCTs of 36 patients in 2011. The foramen was present in every patient examined.

The LF has been defined as a tiny opening in the midline of the lingual region of the jaw. This hole appears as a tiny radiolucent circle roughly one centimeter below the interapical line of the inferior incisors on radiographs. It varies in size, with a diameter that seldom exceeds 1 to 2 mm, as well as in number, length, and placement, all of which make it challenging to detect the LF with conventional radiography (Dreiseidler et al., 2009; Oettlé et al., 2015; Romanos et al., 2012; Rosano et al., 2009; Sahman et al., 2014; Scaravilli et al., 2010; Sekerci et al., 2014; Tagaya et al., 2009).

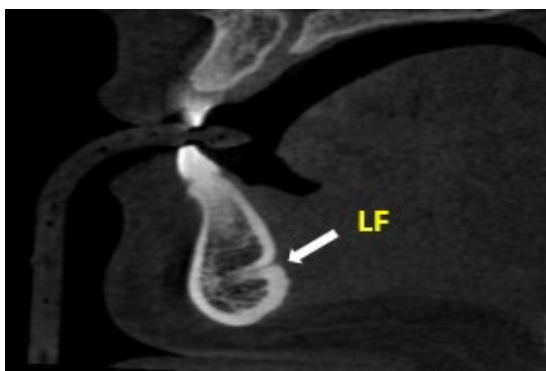In their analysis of 70 individuals' mandibles, Surathu et al. (Surathu et al., 2022) found lingual foramina in a variety of anatomical arrangements. It has been suggested that CBCT be used in the preoperative planning of anterior mandibular surgical operations to reduce the risk of unanticipated bleeding (Figures 1–4).

## Frequency

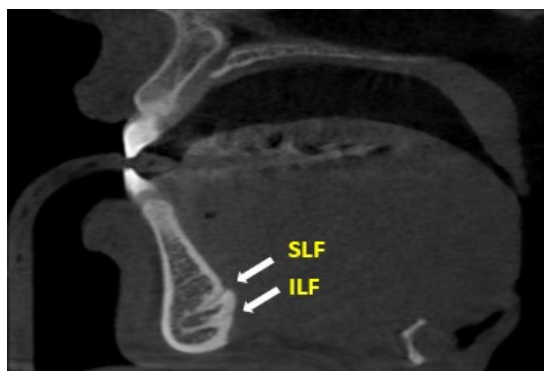
As reported by Laisiroengrai et al. (Laisiroengrai et al., 2022) in their research of 240 patients, midline LF had a 100% frequency. Yu et al. (Yu et al., 2022) demonstrated that at least one lingual foramen was present in 80 CBCT

pictures of elderly Koreans. Likewise, historically, results have shown a high incidence of LF (greater than 90%) (Choi et al., 2013; Wang et al., 2015; Moro et al., 2018; He et al., 2016; Barbosa et al., 2022). Tagaya et al. (Tagaya et al., 2009) used CBCT to study both 5 cadavers and 200 living people. All of the cadavers had foramina, while at least one foramen showed up in 190 of the 200 living. We discovered a 99.3 % prevalence rate. 199 (99.5%) of the women and 102 (99.0%) of the men

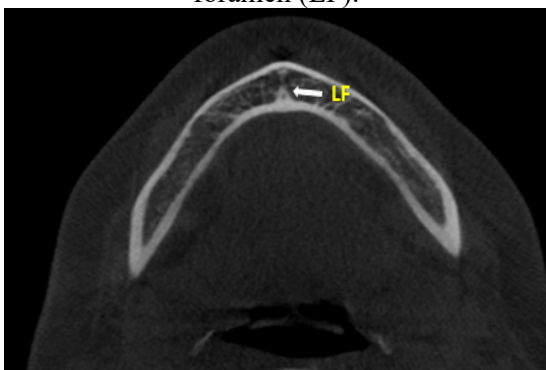
possessed foramina. Alqutaibi et al. (Alqutaibi et al., 2022) have indicated no significant difference between genders in the prevalence of LF. A review by Barbosa et al. (Barbosa et al., 2020) concluded that females were more likely to have it than males. While research by de Andrade Santos et al. (de Andrade Santos et al., 2020) in 2020 found that both men and women had foramina (99.0% and 99.5%, respectively). LF is quite prevalent, and its occurrence has been found to be independent of factors including age, gender, and dental state.



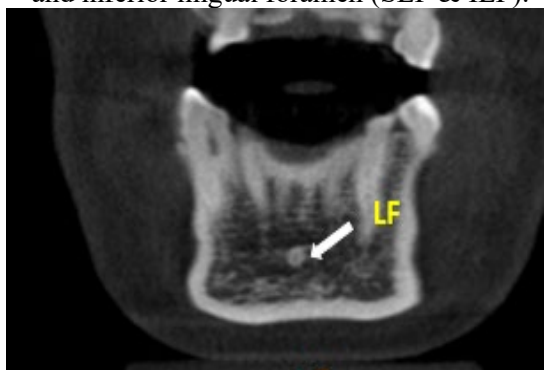**Figure 1:** Sagittal plane of CBCT showed lingual foramen (LF).



**Figure 2:** CBCT sagittal plane showed superior and inferior lingual foramen (SLF & ILF).



**Figure 3:** The CBCT axial plane displays the lingual foramen (LF).



**Figure 4:** Lingual foramen (LF) coronal CBCT imaging.

### Number

Sheikhi et al. (Sheikhi et al., 2012) analyzed the discrepancies between the LF and bone canals of 102 individuals using CBCT. Approximately 52% of the research group had at least one foramen. In addition, the data revealed that as many as four LFs had been discovered. Abesi et al.<sup>44</sup> noted that during an inspection of CBCT data, the most relevant number of canals was two (53%), followed by a single canal (46.5%) and

only in 6.0% of cases, three canals were identified, which is in line with de Andrade Santos et al. (de Andrade Santos et al., 2020) outcome (two: 47.5%; single: 39.5%; and three: 7.5%).

Literature reported that more than three LFs were unusual, with a low prevalence of four LFs ranging from 0.15 to 4% (Abesi et al., 2015; Eshak et al., 2014; Zhang et al., 2018; Katakami et al., 2009; Liang et al., 2009). Despite the fact that previous investigations have

identified up to four LFs (Liang et al., 2009; Aoun et al., 2017). Previously, it was reported that a single LF was the most prevalent (Tepper et al., 2001; Babiuc et al., 2011; Moshfeghi et al., 2021), but other researchers reported a double foramen (Abesi et al., 2015; Kim et al., 2013). According to He et al. (He et al., 2016), the majority of patients had 3 or 4 foramina. In addition, between 0 and 8 foramina were discovered in each subject. Sanchez-Perez et al. (Sanchez-Perez et al., 2018) detected that 64% of individuals had one canal of the LF, 33% had two canals, and 3% had a triple foramen after analyzing 111 CBCTs for implant purposes. In both edentulous and dentate individuals, women exhibited marginally lower values for each variable compared to males. This indicates that the LF must be considered while considering surgery. When determining where to place the dental implant, it is essential to pay special attention to avoid complications.

Bernardi et al. (Bernardi et al., 2014) conducted a study of Dental CT scans on 56 individuals. Seventy-five percent had at least one foramen on the midline of the lingual mandible.

### Location

Several approaches were used to assess the anatomical location of the LF. Marzook et al. (Marzook et al., 2019) categorized it based on the position of the canal opening as upper, middle, and lower, which might be lingual or buccal. As a reference, He et al. (He et al., 2016) utilized the tooth apex (above or below). Another often used genial tubercle has characterized the LF location as superior, medium, or inferior (He et al., 2016; Xie et al., 2019; Romanos et al., 2012). Additional research based on the genial tubercle categorizes it as either upper or lower LF (Marzook et al., 2019; Gilis et al., 2019; Aps, 2014; Bulut and Kose, 2018) Laisiroengrai et al. (Laisiroengrai et al., 2022) and Moshfeghi et al. (Moshfeghi et al., 2021) clarified that the location of LF was commonly in the superior position, followed by the inferior position. Concerning the mandible, 7.7 mm was the

average distance between the LF and inferior border of the mandible (Moshfeghi et al., 2021). This number was somewhat less than what was recorded for this distance (11.5 and 14mm, respectively) (Von et al., 2011; Aoun et al., 2017).

The work of Kawai et al. (Kawai et al., 2007), which discovered that the distance between the inferior LF and the inferior mandibular plane was 4.42 mm while the distance between the superior LF and the inferior mandibular plane was 11.4 mm, supported these findings.

### Diameter

The diameter (D) of the LF was identified to vary from 0.25 to 1.90 mm (mean  $0.61 \pm 0.33$  mm) by Wang et al. (Wang et al., 2015), who were more interested in the bone canals of the mandible within the evaluation, which included 303 CBCT pictures in total. The supraspinosum canals measured an average of  $0.87 \pm 0.03$  mm in D at the lingual terminus (Santos, 2020). According to prior studies, the mean D of the superior LF falls between the ranges of 0.71 and 1.05 mm. In general, the D of the superior LF was bigger than that of the lower LF, and the majority of them ran downward (Von et al., 2011; Makris et al., 2011; Choi et al., 2013; Wang et al., 2015; Moro et al., 2018; He et al., 2016). Nevertheless, prior outcomes found no link between the magnitude of LF and gender or age (Makris et al., 2010; Abesi et al., 2015)

### Lateral lingual foramen (LLF)

Several investigations have found different LLF frequencies. Many studies demonstrated that the premolar area was the most common location for LLF (Sahman et al., 2014; Kim et al., 2013; Xie et al., 2019; Kawai et al., 2007; Sanomiya et al., 2016). Accordingly, Laisiroengrai et al. (Laisiroengrai et al., 2022) found similar results, and its canal course was usually in the anterior direction. There was a greater incidence of LLF in males. Conversely, a study of Indian cadavers found that LLF was more prevalent in the canine area (Murlimanju et al., 2012).

### Recommendation

The lingual foramen and the LLF identification are useful in that they may aid in the prevention of surgical problems during surgery. Recently, dental implants have been recognized as the principal choice for the prosthetic rehabilitation of individuals with missing teeth. In many instances, implant implantation is a regular and predictable procedure. However, surgery in the anterior mandible may cause rupture of the lingual periosteum, forming a hematoma in this location, followed by enlargement of the floor of the mouth and obstruction of the upper airway. Thus, pre-operative planning should incorporate radiological imaging to minimize complications. Especially, the literature recorded that LLF communicated with the mandibular canal in the premolar area.

### Conclusion

The LF and canal must be evaluated before surgery to avoid intra-operative and postoperative problems such as bleeding. The LLF and its canal can be identified by CBCT. In the premolar locations, operators should take LLF into account while placing mandibular implants. The identification of up to four LFs and a similarly low proportion of the accessory LFs are notable.

### Supplementary Material

None.

### Funding

This research received no external funding.

### Data Availability Statement

Data are available from the authors upon reasonable request.

### Conflict of interest

The authors reported that they have no conflicts of interest.

### Acknowledgments

The authors would like to thank Mustansiriya University ([www.uomustansiriyah.edu.iq](http://www.uomustansiriyah.edu.iq)),

Baghdad, Iraq, for their support in the present work.

### References

1. Balaguer Marti, J.C., Guarinos, J., Serrano Sánchez, P., Ruiz Torner, A., Peñarocha Oltra, D. and Peñarocha Diago, M. (2016) 'Review of the arterial vascular anatomy for implant placement in the anterior mandible', *Journal of Oral Science & Rehabilitation*, 2(1), pp. 32–39.
2. Neves, F.S., Vasconcelos, T.V., Oenning, A.C., de-Azevedo-Vaz, S.L., Almeida, S.M. and Freitas, D.Q. (2014) 'Oblique or orthoradial CBCT slices for preoperative implant planning: which one is more accurate?', *Brazilian Journal of Oral Sciences*, 13(2), pp. 104–108. Available at: <https://doi.org/10.1590/1677-3225v13n2a05>.
3. Wang, M.F., Xie, X., Li, G. and Zhang, Z. (2020) 'Relationship between CNR and visibility of anatomical structures of cone-beam computed tomography images under different exposure parameters', *Dentomaxillofacial Radiology*, 49(5), p. 20190336. Available at: <https://doi.org/10.1259/dmfr.20190336>.
4. Gaêta-Araujo, H., Alzoubi, T., Vasconcelos, K.F., Orhan, K., Pauwels, R., Casselman, J.W. and Jacobs, R. (2020) 'Cone beam computed tomography in dentomaxillofacial radiology: a two-decade overview', *Dentomaxillofacial Radiology*, 49(8), p. 20200145. Available at: <https://doi.org/10.1259/dmfr.20200145>.
5. Liang, H., Frederiksen, N.L. and Benson, B.W. (2004) 'Lingual vascular canals of the interforaminal region of the mandible: evaluation with conventional tomography', *Dentomaxillofacial Radiology*, 33(5), pp. 340–341. Available at: <https://doi.org/10.1259/dmfr/33787240>.
6. Gahleitner, A., Hofschneider, U., Tepper, G., Pretterklieber, M., Schick, S., Zauza, K. and Watzek, G. (2001) 'Lingual vascular canals of the mandible: evaluation with dental CT', *Radiology*, 220(1), pp. 186–189. Available at: <https://doi.org/10.1148/radiology.220.1.r01j105186>.
7. Peñarocha-Diago, M., Balaguer-Martí, J.C., Peñarocha-Oltra, D., Bagán, J., Peñarocha-

- Diago, M. and Flanagan, D. (2019) 'Floor of the mouth hemorrhage subsequent to dental implant placement in the anterior mandible', *Clinical, Cosmetic and Investigational Dentistry*, 11, pp. 235–242. Available at: <https://doi.org/10.2147/CCIDE.S207120>.
8. Jacobs, R., Lambrichts, I., Liang, X., Martens, W., Mraiwa, N., Adriaenssens, P. and Gelan, J. (2007) 'Neurovascularization of the anterior jaw bones revisited using high-resolution magnetic resonance imaging', *Oral Surgery, Oral Medicine, Oral Pathology, Oral Radiology, and Endodontology*, 103(5), pp. 683–693. Available at: <https://doi.org/10.1016/j.tripleo.2006.11.014>.
9. Mraiwa, N., Jacobs, R., Moerman, P., Lambrichts, I., van Steenberghe, D. and Quirynen, M. (2003) 'Presence and course of the incisive canal in the human mandibular interforaminal region: two-dimensional imaging versus anatomical observations', *Surgical and Radiologic Anatomy*, 25(5–6), pp. 416–423. Available at: <https://doi.org/10.1007/s00276-003-0152-8>.
10. Tepper, G., Hofschneider, U., Gahleitner, A. and Ulm, C. (2001) 'Computed tomographic diagnosis and localization of bone canals in the mandibular interforaminal region for prevention of bleeding complications during implant surgery', *The International Journal of Oral & Maxillofacial Implants*, 16(1), pp. 68–72.
11. Mardinger, O., Chaushu, G., Arensburg, B., Taicher, S. and Kaffe, I. (2000) 'Anatomic and radiologic course of the mandibular incisive canal', *Surgical and Radiologic Anatomy*, 22(3–4), pp. 157–161. Available at: <https://doi.org/10.1007/s00276-000-0157-5>.
12. McDonnell, D., Nouri, M.R. and Todd, M.E. (1994) 'The mandibular lingual foramen: a consistent arterial foramen in the middle of the mandible', *Journal of Anatomy*, 184(2), pp. 363–369.
13. Liang, X., Jacobs, R. and Lambrichts, I. (2007) 'Lingual foramina on the mandibular midline revisited: a macroanatomical study', *Clinical Anatomy*, 20(3), pp. 246–251. Available at: <https://doi.org/10.1002/ca.20357>.
14. von Arx, T., Matter, D., Buser, D. and Bornstein, M.M. (2011) 'Evaluation of location and dimensions of lingual foramina using limited cone-beam computed tomography', *Journal of Oral and Maxillofacial Surgery*, 69(11), pp. 2777–2785. Available at: <https://doi.org/10.1016/j.joms.2011.06.198>.
15. Babiuc, I., Tărlungeanu, I. and Păuna, M. (2011) 'Cone beam computed tomography observations of the lingual foramina and their bony canals in the median region of the mandible', *Romanian Journal of Morphology and Embryology*, 52(3), pp. 827–829.
16. Mun, M.J., Lee, C.H., Lee, B.J., Choi, Y., Kim, H.J. and Won, J.H. (2016) 'Histopathologic evaluations of the lingual artery in healthy tongue of adult cadaver', *Clinical and Experimental Otorhinolaryngology*, 9(3), pp. 257–262. Available at: <https://doi.org/10.21053/ceo.2015.01137>.
17. Mei, J., Liu, Y., Zhao, H., Liu, B., Xu, S. and Wu, J.F. (2007) 'The study of clinical anatomy of lingual artery in physiological condition', *Lin Chuang Er Bi Yan Hou Tou Jing Wai Ke Za Zhi*, 21(9), pp. 396–399.
18. Isaacson, T.J. (2004) 'Sublingual hematoma formation during immediate placement of mandibular endosseous implants', *The Journal of the American Dental Association*, 135(2), pp. 168–172. Available at: <https://doi.org/10.14219/jada.archive.2004.0148>.
19. Longoni, S., Sartori, M., Braun, M., Lumbau, A., Lumbau, A.I., Meloni, S.M., Tallarico, M. and Baldoni, E. (2007) 'Lingual vascular canals of the mandible: the risk of bleeding complications during implant procedures', *Implant Dentistry*, 16(2), pp. 131–138. Available at: <https://doi.org/10.1097/ID.0b013e31805009d5>.
20. Loukas, M., Kinsella, C.R., Kapos, T., Tubbs, R.S. and Ramachandra, S. (2008) 'Anatomical variation in arterial supply of the mandible with special regard to implant placement', *International Journal of Oral and Maxillofacial Surgery*, 37(4), pp. 367–371. Available at: <https://doi.org/10.1016/j.ijom.2007.11.007>.
21. Makris, N., Stamatakis, H., Syriopoulos, K., Tsiklakis, K. and van der Stelt, P.F. (2010) 'Evaluation of the visibility and the course of the mandibular incisive canal and the lingual foramen using cone-beam computed

tomography', *Clinical Oral Implants Research*, 21(7), pp. 766–771. Available at: <https://doi.org/10.1111/j.1600-0501.2009.01903.x>.

22. Stuart, J. (2015) 'Implant complications associated with two and three dimensional diagnostic imaging technologies', in Ganz, S.D. (ed.) *Dental implant complications: etiology, prevention, and treatment*. 2nd edn. Hoboken, NJ: John Wiley & Sons, pp. 102–131. Available at: <https://doi.org/10.1002/9781119140474.ch5>.

23. Sanchez-Perez, A., Boix-Garcia, P. and Lopez-Jornet, P. (2018) 'Cone-beam CT assessment of the position of the medial lingual foramen for dental implant placement in the anterior symphysis', *Implant Dentistry*, 27(1), pp. 43–48. Available at: <https://doi.org/10.1097/ID.0000000000000719>.

24. Dreiseidler, T., Mischkowski, R.A., Neugebauer, J., Ritter, L. and Zöller, J.E. (2009) 'Comparison of cone-beam imaging with orthopantomography and computerized tomography for assessment in presurgical implant dentistry', *The International Journal of Oral & Maxillofacial Implants*, 24(2), pp. 216–225.

25. Oettlé, A.C., Fourie, J., Human-Baron, R. and van Zyl, A.W. (2015) 'The midline mandibular lingual canal: importance in implant surgery', *Clinical Implant Dentistry and Related Research*, 17(1), pp. 93–101. Available at: <https://doi.org/10.1111/cid.12080>.

26. Romanos, G.E., Gupta, B. and Crespi, R. (2012) 'Endosseous arteries in the anterior mandible: literature review', *The International Journal of Oral & Maxillofacial Implants*, 27(1), pp. 90–94.

27. Rosano, G., Taschieri, S., Gaudy, J.F., Weinstein, T. and Del Fabbro, M. (2009) 'Anatomic assessment of the anterior mandible and relative hemorrhage risk in implant dentistry: a cadaveric study', *Clinical Oral Implants Research*, 20(8), pp. 791–795. Available at: <https://doi.org/10.1111/j.1600-0501.2009.01713.x>.

28. Sahman, H., Sekerci, A.E. and Ertas, E.T. (2014) 'Lateral lingual vascular canals of the mandible: a CBCT study of 500 cases', *Surgical and Radiologic Anatomy*, 36(9), pp. 865–870.

Available at: <https://doi.org/10.1007/s00276-014-1258-x>.

29. Scaravilli, M.S., Mariniello, M. and Sammartino, G. (2010) 'Mandibular lingual vascular canals (MLVC): evaluation on dental CTs of a case series', *European Journal of Radiology*, 76(2), pp. 173–176. Available at: <https://doi.org/10.1016/j.ejrad.2009.06.002>.

30. Sekerci, A.E., Sisman, Y. and Payveren, M.A. (2014) 'Evaluation of location and dimensions of mandibular lingual foramina using cone-beam computed tomography', *Surgical and Radiologic Anatomy*, 36(9), pp. 857–864. Available at: <https://doi.org/10.1007/s00276-014-1311-9>.

31. Tagaya, A., Matsuda, Y., Nakajima, K., Seki, K., Okano, T. and Ozawa, H. (2009) 'Assessment of the blood supply to the lingual surface of the mandible for reduction of bleeding during implant surgery', *Clinical Oral Implants Research*, 20(4), pp. 351–355. Available at: <https://doi.org/10.1111/j.1600-0501.2008.01668.x>.

32. Surathu, N., Flanagan, D., Surathu, N. and Nittla, P.P. (2022) 'A CBCT assessment of the incidence and location of the lingual foramen in the anterior mandible', *Journal of Oral Implantology*, 48(2), pp. 92–98. Available at: <https://doi.org/10.1563/aaid-joi-D-19-00299>.

33. Laisiroengrai, T., Pornprasertsuk-Damrongrsi, S. and Sirintawat, N. (2022) 'Prevalence of lingual canals and their foramina in a group of Thai people using cone-beam computed tomography', *M Dent Journal*, 42(2), pp. 129–136.

34. Yu, S.K., Lim, J., Bae, C.J., Seo, Y.S. and Kim, H.J. (2022) 'Morphometric analysis of the mandibular lingual foramina using cone-beam computed tomography in elderly Korean', *International Journal of Morphology*, 40(3), pp. 688–696. Available at: <https://doi.org/10.4067/S0717-95022022000300688>.

35. Choi, D.Y., Woo, Y.J., Won, S.Y., Kim, D.H., Kim, H.J. and Hu, K.S. (2013) 'Topography of the lingual foramen using micro-computed tomography for improving safety during implant placement of anterior mandibular region', *The Journal of Craniofacial Surgery*, 24(4), pp. 1403–1407. Available

at: <https://doi.org/10.1097/SCS.0b013e31828b75da>.

36. Wang, Y.M., Ju, Y.R., Pan, W.L. and Chan, C.P. (2015) 'Evaluation of location and dimensions of mandibular lingual canals: a cone beam computed tomography study', *International Journal of Oral and Maxillofacial Surgery*, 44(10), pp. 1197–1203. Available

at: <https://doi.org/10.1016/j.ijom.2015.03.014>.

37. Moro, A., Abe, S., Yokomizo, N., Kobayashi, Y., Ono, T. and Takeda, T. (2018) 'Topographical distribution of neurovascular canals and foramina in the mandible: avoiding complications resulting from their injury during oral surgical procedures', *Heliyon*, 4(7), p. e00812. Available

at: <https://doi.org/10.1016/j.heliyon.2018.e00812>.

38. He, X., Jiang, J., Cai, W., Pan, Y., Yang, Y., Zhu, K. and Zheng, Y. (2016) 'Assessment of the appearance, location and morphology of mandibular lingual foramina using cone beam computed tomography', *International Dental Journal*, 66(5), pp. 272–279. Available

at: <https://doi.org/10.1111/idj.12242>.

39. Barbosa, D.A.F., de Mendonça, D.S., de Carvalho, F.S.R., de Oliveira, D., Martins, L.H.D., Rocha, A.C., de Oliveira, R.C. and Haiter-Neto, F. (2022) 'Systematic review and meta-analysis of lingual foramina anatomy and surgical-related aspects on cone-beam computed tomography: a PROSPERO-registered study', *Oral Radiology*, 38(1), pp. 1–16. Available at: <https://doi.org/10.1007/s11282-021-00516-8>.

40. Alqutaibi, A.Y., Alassaf, M.S., Elsayed, S.A., Alharbi, A.S., Habeeb, A.T., Alqurashi, M.A., Albulushi, K.A., Elboraey, M.O., Alsultan, K. and Mahmoud, I.I. (2022) 'Morphometric analysis of the midline mandibular lingual canal and mandibular lingual foramina: a cone beam computed tomography (CBCT) evaluation', *International Journal of Environmental Research and Public Health*, 19(24), p. 16910. Available

at: <https://doi.org/10.3390/ijerph192416910>.

41. de Andrade Santos, J.B., de Brito, F.C. and e Mello Dias, E.C. (2020) 'Prevalence of lingual foramina in the anterior mandible: a cone-

beam computed tomography study', *Journal of Oral and Maxillofacial Radiology*, 8(1), pp. 10–15. Available

at: [https://doi.org/10.4103/jomr.jomr\\_4\\_20](https://doi.org/10.4103/jomr.jomr_4_20).

42. Sheikhi, M., Mosavat, F. and Ahmadi, A. (2012) 'Assessing the anatomical variations of lingual foramen and its bony canals with CBCT taken from 102 patients in Isfahan', *Dental Research Journal*, 9(1), pp. 45–51.

43. Abesi, F., Ehsani, M., Haghanifar, S. and Sohanian, S. (2015) 'Assessing the anatomical variations of lingual foramen and its bony canals with CBCT', *International Journal of Sciences: Basic and Applied Research*, 20(2), pp. 220–227.

44. Eshak, M., Brooks, S., Abdel-Wahed, N. and Edwards, P.C. (2014) 'Cone beam CT evaluation of the presence of anatomic accessory canals in the jaws', *Dentomaxillofacial Radiology*, 43(1), p. 20130259. Available

at: <https://doi.org/10.1259/dmfr.20130259>.

45. Zhang, C., Zhuang, L., Fan, L., Mo, J., Huang, Z. and Gu, Y. (2018) 'Evaluation of mandibular lingual foramina with cone-beam computed tomography', *The Journal of Craniofacial Surgery*, 29(2), pp. 389–394. Available

at: <https://doi.org/10.1097/SCS.00000000000004390>.

46. Katakami, K., Mishima, A., Kuribayashi, A., Shimoda, S., Hamada, Y. and Kobayashi, K. (2009) 'Anatomical characteristics of the mandibular lingual foramen observed on limited cone-beam CT images', *Clinical Oral Implants Research*, 20(4), pp. 386–390. Available

at: <https://doi.org/10.1111/j.1600-0501.2008.01632.x>.

47. Liang, X., Jacobs, R., Corpas, L.S., Semal, P. and Lambrichts, I. (2009) 'Chronologic and geographic variability of neurovascular structures in the human mandible', *Forensic Science International*, 190(1–3), pp. 24–32. Available

at: <https://doi.org/10.1016/j.forsciint.2009.05.006>.

48. Aoun, G., Nasseh, I., Sokhn, S. and Rifai, M. (2017) 'Lingual foramina and canals of the mandible: anatomic variations in a Lebanese population', *Journal of Clinical Imaging Science*, 7, p. 16. Available

at: [https://doi.org/10.4103/jcis.JCIS\\_15\\_17](https://doi.org/10.4103/jcis.JCIS_15_17).

49. Moshfeghi, M., Gandomi, S., Mansouri, H. and Yadshoghi, N. (2021) 'Lingual foramen of the mandible on cone-beam computed tomography scans: a study of anatomical variations in an Iranian population', *Frontiers in Dentistry*, 18, p. 20. Available at: <https://doi.org/10.18502/ffd.v18i20.6327>.
50. Kim, D.H., Kim, M.Y. and Kim, C.H. (2013) 'Distribution of the lingual foramina in mandibular cortical bone in Koreans', *Journal of the Korean Association of Oral and Maxillofacial Surgeons*, 39(6), pp. 263–268. Available at: <https://doi.org/10.5125/jkaoms.2013.39.6.263>.
51. Bernardi, S., Rastelli, C., Leuter, C., Varvara, G., Greco, A.G., Piro, C., Continenza, M.A. and Gatto, R. (2014) 'Anterior mandibular lingual foramina: an in vivo investigation', *Anatomy Research International*, 2014, p. 906348. Available at: <https://doi.org/10.1155/2014/906348>.
52. Marzook, H.A., El-Gendy, A.A. and Darweesh, F.R.S. (2019) 'Median perforating canal in human mandible', *The Journal of Craniofacial Surgery*, 30(2), pp. 430–432. Available at: <https://doi.org/10.1097/SCS.00000000000005460>.
53. Xie, L., Li, T., Chen, J., Yin, D., Wang, W. and Xie, Z. (2019) 'Cone-beam CT assessment of implant-related anatomy landmarks of the anterior mandible in a Chinese population', *Surgical and Radiologic Anatomy*, 41(8), pp. 927–934. Available at: <https://doi.org/10.1007/s00276-019-02250-7>.
54. Romanos, G.E., Gupta, B., Davids, R., Damouras, M. and Crespi, R. (2012) 'Distribution of endosseous bony canals in the mandibular symphysis as detected with cone beam computed tomography', *The International Journal of Oral & Maxillofacial Implants*, 27(1), pp. 273–277.
55. Gilis, S., Dhaene, B., Dequanter, D. and Loeb, I. (2019) 'Mandibular incisive canal and lingual foramina characterization by cone-beam computed tomography', *Morphologie*, 103(341), pp. 48–53. Available at: <https://doi.org/10.1016/j.morpho.2018.12.005>.
56. Aps, J.K. (2014) 'Number of accessory or nutrient canals in the human mandible', *Clinical Oral Investigations*, 18(2), pp. 671–676. Available at: <https://doi.org/10.1007/s00784-013-1011-6>.
57. Bulut, G.D. and Kose, E. (2018) 'Available bone morphology and status of neural structures in the mandibular interforaminal region: three dimensional analysis of anatomical structures', *Surgical and Radiologic Anatomy*, 40(11), pp. 1243–1252. Available at: <https://doi.org/10.1007/s00276-018-2039-8>.
58. Kawai, T., Asaumi, R., Sato, I., Yoshida, S. and Yosue, T. (2007) 'Classification of the lingual foramina and their bony canals in the median region of the mandible: cone beam computed tomography observations of dry Japanese mandibles', *Oral Radiology*, 23(1), pp. 42–48. Available at: <https://doi.org/10.1007/s11282-007-0064-0>.
59. Sanomiya Ikuta, C.R., Paes da Silva Ramos Fernandes, L.M., Poleti, M.L., Alvares Capelozza, A.L. and Fischer Rubira-Bullen, I.R. (2016) 'Anatomical study of the posterior mandible: lateral lingual foramina in cone beam computed tomography', *Implant Dentistry*, 25(2), pp. 247–251. Available at: <https://doi.org/10.1097/ID.0000000000000387>.
60. Murlimanju, B.V., Prakash, K.G., Samiullah, D., Prabhu, L.V., Pai, M.M., Vadgaonkar, R., Bhat, K.M. and Kumar, C.G. (2012) 'Accessory neurovascular foramina on the lingual surface of mandible: incidence, topography, and clinical implications', *Indian Journal of Dental Research*, 23(3), p. 433. Available at: <https://doi.org/10.4103/0970-9290.102252>.