



Surgical removal of a large submandibular salivary stone Case report

Dr. Faaiz Y. Alhamdani B.D.S, M.Sc*

Dr. Ahmed F. Alhadithi B.D.S. **

Abstract

A twenty-six years male, presented to the oral surgery clinic, complaining from recurrent sub mandibular swelling in the left side, due to sub mandibular stone in the left Wharton's duct. The size of the stone is relatively large. In this case report, we will discuss the possible cause for such large size of the stone and the technique of surgical removal.

Key words: surgical removal, sub mandibular, large salivary stone.

Introduction

The formation of stones, or calculi, may occur throughout the body, including the gallbladder, urinary tract, and salivary glands ⁽¹⁾. Salivary stone occasionally forms in a salivary gland or duct, usually by deposition of calcium salts around a nidus of organic material, and has a layered microscopic structure ⁽²⁾ Salivary gland stones are the most common disease of salivary glands. It is estimated that it affects 12 in 1000 of the adult population.⁽³⁾ Males are affected twice as much as females⁽⁴⁾ Children are rarely affected but a review of the literature reveals 100 cases of sub mandibular calculi in children aged 3 weeks to 15 years old.⁽⁵⁾ The peak incidence of salivary gland stones is between ages 30 and 50 ⁽¹⁾. Large sialoliths have rarely been reported in the salivary ducts ⁽⁶⁾.

Salivary gland stones (calculi) are the commonest intra luminal cause of recurrent salivary gland swelling. Sub mandibular calculi are the most common ⁽⁴⁾ Submandibular

sialolithiasis is more common as its saliva is (i) more alkaline, (ii) has an increased concentration of calcium and phosphate, and (iii) has a higher mucous content than saliva of the parotid and sublingual glands. ⁽⁴⁾, ⁽⁷⁾ In addition, the submandibular duct is longer and the gland has an antigravity flow.⁽⁴⁾.

Almost half of the sub mandibular calculi lie in the distal third of the duct and are amenable to simple surgical release through an incision in the floor of the mouth, which is relatively simple to perform and not usually associated with complications.⁽⁸⁾

Although surgical removal of sub mandibular stone still popular, recently; both minimally invasive, and conservative approaches for the diagnosis and treatment of salivary gland stones, were introduced, such as sialoendoscopy and extracorporeal shock wave lithotripsy (ECSWL).

These techniques proved to be successful in the treatment of small salivary gland (less than 3 mm) ⁽¹⁾.

* Assistant lecturer. Oral surgery department/ college of dentistry, Al-mustansiria University.

** Periodontology department /college of dentistry-University of Baghdad.

Case history

A twenty-six years male referred to oral surgery department in Alkarama specialized dentistry center, complaining from recurrent sub mandibular swelling in the left side of 10 years duration with duration between episodes about 1-2 years duration. The patient used to deal with the condition by antibiotics and some times with the aid of sub mandibular massage with discharge of saliva and pus which give him relief for several months.

Few days ago he recalled his dentist who suspected the presence of a stone in the sub mandibular duct as he notices a swelling along the course of the left sub mandibular gland. Occlusal radiograph was taken; it shows an egg shaped radiopaque mass, which confirmed the diagnosis.

Surgical procedure

After taking the patient medical history, a thorough clinical examination was done to assess the exact position of the stone to see the possibility to remove the stone under local anesthesia

A preoperative prophylactic dose of Lincocine 600-mg was administered I.M., 30 min. before incision making. Lingual anesthesia was given afterward.

The tongue was retracted by a piece of gauze. The duct sutured loosely behind the stone to prevent its posterior dislodgment, about 3-cm mucosal incision was performed against the stone position in the longitudinal axis of the duct. Upon dissection to reach the stone sublingual salivary gland structure encountered, it was a little bit difficult to expose the stone after incising the duct lining because the fibrous adhesions resulting from recurrent inflammatory processes.

After its exposure, we grasped the stone gently by mosquito artery forceps, and the adhesions were relieved by excavator end of the surgical cumine, which facilitate its removal. The size of the stone was 2 by 1cm.

Copious irrigation and suction was done to ensure removal of possible minor stones posterior to the removed stone, and a clear mucous secretion was noticed through the wound incision. After ensuring homeostasis, Closure of mucosal wound was done with 3/0 silk suture. Postoperative analgesic and antiseptic mouthwash were prescribed

Discussion

It's not known why some sub mandibular stone reach to a considerably large size before the patients seek the treatment, and the available data doesn't give us a clue ⁽⁶⁾. In this case we believe that continuous milking procedures and over a long period of time, has delayed the incidence of total duct obstruction which allow the saliva to bypass the gradually enlarging stone before total duct obstruction. Recurrent swellings which has been managed by the patient by milking of the duct, reflects that there was a recurrent attempts for formation of stone in the duct, but in this case, his measures to milk the stone failed. Recurrent inflammatory process of the duct, imposed it self as technical difficulty in surgical manipulation. Long incision (more than the estimated length of the stone) will provide adequate accessibility and insure more control. Removal of long standing salivary gland stone requires a delicate and careful handling to avoid unnecessary damage to the duct and adjacent structures. Ensuring homeostasis before suturing is of

crucial importance, as it prevents postoperative haematoma.

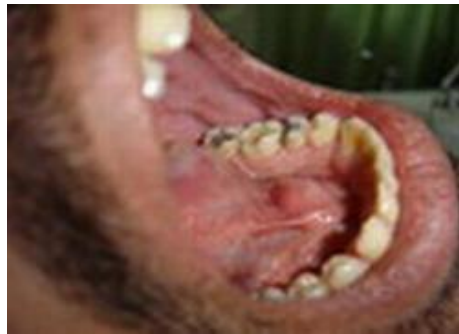Conclusion

Although new conservative technique were introduced recently for the treatment of sub mandibular stones, no data available supports its effectiveness in the treatment of large salivary gland stones, in fact large size stones has resulted in technical failures in some cases treated with extracorporeal shock wave lithotripsy⁽⁹⁾.

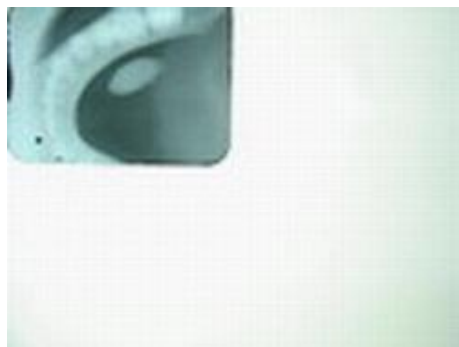
Intra-oral surgical approach for removal of large sub mandibular stone is still effective, safe, and can minimize the incidence of further sub mandibular stone formation through the duct revision⁽¹⁾.

References

- 1- Michad Miloro and Sterling R. Schow; Diagnosis and management of salivary gland disorders; chapter 20; contemporary oral and maxillofacial surgery; 2003; 442.
- 2- R.A. Cawson; Diseases of the salivary glands; essentials of dental surgery and pathology; 1993 chapter 17; 395.
- 3- Rauch S, Gorlin R J. Disease of the salivary glands. In: Gorlin R J, Goldmann H M, eds. Thomas' Oral Pathology. St Loius, Mo: Mosby-Year Book Inc; 1970: 997-1003.
- 4- Leung A K, Choi M C, Wagner G A. Multiple sialoliths and a sialolith of unusual size in the submandibular duct. Oral Surg, Oral Med, Oral Pathol, Oral Radiol, Endo 1999; 87: 331-333.
- 5- Cawson R A, Odell E W. Essentials of oral pathology and oral medicine. Edinburgh: Churchill Livingstone, 6th ed. 1998; pp 239-240.
- 6- S. J. Siddiqui; Sialolithiasis: an unusually large submandibular salivary stone: B.D.J. JULY 27 2002, VOLUME 193, No. 2, PAGES 89-91
- 7- Steiner M, Gould A R, Kushner G M, Weber R, Pesto A. Sialolithiasis of the submandibular gland in an 8-year-old child. Oral Surg, Oral Med, Oral Pathol, Oral Radiol, Endod 1997; 83: 188.
- 8- Zakaria M A. Giant calculi of the submandibular salivary gland. Br J Oral Surg 1981; 19: 230-232.
- 9- Robert (Byung) H. Kim. Nonoperative Removal of Sialoliths and Sialodochoplasmy of Salivary Duct Strictures. Arch Otolaryngology Head Neck Surgery 1996;122:974-976



Intra oral photograph shows the position of the stone



Occlusal radiograph, clearly demonstrate the size and the site of the stone



The stone after removal