



## Ear lobes as facial landmarks for determining the occlusal plane

**Dr. Bayan S. Khalaf, B.D.S. M.Sc.\***

### Abstract

**Aim of the study:** The aim of this study was to introduce ear lobes as alternative landmarks for the interpupillary line during orientation of the occlusal plane. Also, the other aim was to compare the ear lobes with the pupils of the eyes to verify that they were indifferent as anatomical landmarks.

**Method:** The alternative landmarks, ear lobes, were presented and the method for orienting the occlusal plane with these landmarks was introduced. Digital pictures of 30 subjects, who participated in the study, were analyzed to compare the parallelism of the interpupillary line with the ear lobes.

**Results:** The results of this study showed that the interpupillary line was parallel with the line drawn between both ear lobes for the same subject.

**Conclusion:** The ear lobes were reliable and dependable alternative landmarks for the orientation of the occlusal plane and could be used with less effort than that of the conventional method utilizing the interpupillary line.

**Key words:** Ear Lobe, facial landmark, occlusal plane, complete denture.

### Introduction

The occlusal plane can be defined as "the average plane established by the incisal and occlusal surfaces of the teeth".<sup>1</sup> The orientation of the occlusal plane is one of the steps needed in determining the maxillo-mandibular relationship and, eventually in the arrangement of the artificial teeth during complete denture construction. This could be achieved by contouring the maxillary occlusal rim to achieve an occlusal plane which lies parallel with facial guides, interpupillary and Camper's (ala-tragus) lines. An occlusal plane indicator such as a Fox plane guide could be used to achieve this goal.<sup>2,3</sup>

There were several authors who used different methods or designed

instruments to help in obtaining the occlusal plane. One of those authors was Pound<sup>4</sup> who favored placing the patient's head in a perfectly erect position and made the occlusal plane parallel to the floor regardless of the eyes or any other facial features. Kazanoglu & Unger<sup>5</sup> determined the occlusal plane with a Camper's plane indicator which consisted of two parallel metal plates. The lower plate was inserted in the mouth and pressed against the upper occlusal rim while the upper plate was used to compare with the interpupillary and camper's lines. Husseinovitch & Chidiac<sup>6</sup> used a modified occlusal plane indicator which is a fox plane guide with two rulers fixed with three long screws. The rulers were used for illustrating the interpupillary and camper's lines.

\* Assistant lecturer at the Department of Prosthodontics, Collage of Dentistry, Baghdad University.

Nayer<sup>7</sup> pressed a piece of string, immersed in talcum powder or plaster of Paris, against the patient's cheeks to mark the Camper's line.

Some authors suggested other facial landmarks like Zepa and Huggare<sup>8</sup> who introduced the supra-orbital line in postero-anterior cephalograms as a substitute for the interpupillary line.

In this article the ear lobes were presented as alternative landmarks for orienting the occlusal plane instead of the pupils of the eyes, interpupillary line. Also, the ear lobes were compared with the pupils to verify that they were indifferent from the pupils as anatomical landmarks.

## Materials & Method

The ear lobes can be used during maxillo-mandibular relationship registration. This is commenced by comparing the Fox plane guide with the ear lobes on both sides simultaneously, as in figure (1). The distance between the inferior border of the ear lobe and the Fox plane guide should be equal on both sides and this is estimated with the practitioner's eyes. Any discrepancies can be adjusted by adding or removing from the occlusal rim.

In this research 30 subjects participated with an age range of 22-40 years.

A digital picture was taken from the frontal view of each subject with the head in an upright position. Each picture was then analyzed in a computer with the Dimaxis 2.3.3 software by Planmeca. Two lines were drawn; the first (P) passing through the center of the pupil and the second (E) passing through the inferior border of both ear lobes of each subject, as seen in figure (2). A third line (T) (transversal line) was drawn crossing the previous two lines, thus creating two corresponding angles. The angle

between lines (P) and (T) was named (PT) and the angle between lines (E) and (T) was named (ET).

The angles were then measured with the same software, Dimaxis 2.3.3 software. The unit in which the angles were measured was in degree (°) which was converted to the Système International d'Unités (SI unit) which was in radian (rad).

The two angles, (PT) and (ET), were compared with each other and statistically analyzed for any significant difference with the Statistical Package for Social Sciences (SPSS) version 15.0 for Windows. The Paired-Sample T Test was used for analysis of the data.

## Results

The (PT) and (ET) angles displayed a mean difference of 0.000233 rad (0.013°), table (1). This difference between the angles was statistically insignificant. This demonstrated that the two corresponding angles for each subject were to a great degree equal to each other and the slight difference was statistically insignificant.

## Discussion

Determining the Occlusal plane during interarch relationship registration in completely edentulous subjects is quite confusing, especially for less experienced practitioners who are attempting to align the occlusal plane with the interpupillary line. This difficulty arises from the fact that trying to imagine the interpupillary line and comparing it with the Fox plane guide is quite difficult and not more difficult than holding any instrument over the movable pupils just to demonstrate the interpupillary line. Also, it's more difficult for the practitioner to compare between the

fox plane guide and an instrument that represents the interpupillary line with a distance of several centimeters apart. A comparison of a centimeter, more or less, for the distance between the ear lobes and the fox plane guide is much easier.

This alternative method is very simple and needs no extra effort as compared to the conventional technique which depends on the pupils to orient the occlusal plane. This method is also easier and less confusing to the dental practitioner. The practitioner would not need to imagine or try to present the interpupillary line with any instrument. The Fox plane guide would just be compared with the inferior border of ear lobes on both sides simultaneously with the practitioner's eye while standing in front of the patient (figure 1).

The ear lobes are stable landmarks unlike the moving pupils of the patient. It's difficult to fix or stabilize the pupils because the patient doesn't understand the importance of stabilizing the pupils, nor does he/she know in which correct position to stabilize the pupils.

In elderly subjects who receive the majority of the complete dentures the muscle coordination is poor.<sup>3</sup> The method suggested in this study was, thus, favorable because no effort was need from the patient.

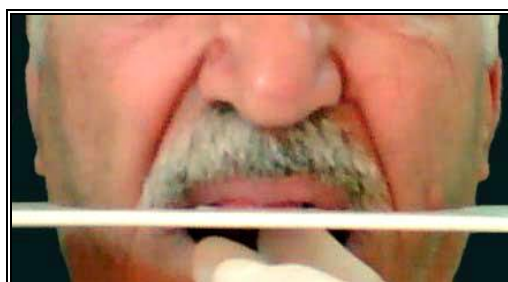The human face is not perfectly symmetrical and what implies on the ear lobes also implies on the pupils of the same face. Furthermore, a range of facial asymmetries that can influence the choice of occlusal plane during prosthodontic treatment exists. Thus, an occlusal plane parallel to the ala tragus and interpupillary lines, as often supported by prosthodontists, may result in less than ideal esthetics in the final restoration.<sup>9</sup>

It was obvious from the results, as seen in table (1), that the corresponding angles (PT) and (ET) were insignificantly different and this meant that lines (P) and (E) were parallel. This is true because when a transversal line cuts two lines, if the corresponding angles are equal in size, then the two lines are parallel.<sup>10</sup>

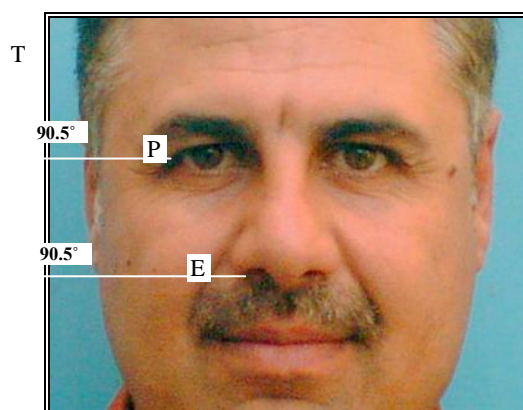
The ear lobes are, thus, reliable and dependable alternative landmarks for the orientation of the occlusal plane and can be used with less effort than that of the conventional method utilizing the interpupillary line.

## References

- 1- The glossary of prosthodontic terms. 7th ed. J Prosthet Dent 1999; 81: 39-110.
- 2- Fox FA. The principles involved in full upper and lower denture construction. Dental Cosmos 1924; 66: 151-157.
- 3- Zarb GA, Bolender CL, Eckert SE, Fenton AH, Jacob RF, Mericske-Stern R. Prosthodontic Treatment for Edentulous Patients: Complete Dentures and Implant-Supported Prosthesis. 12th ed. St. Louis(MO): CV Mosby; 2004. pp.27-8,262-3.
- 4- Pound E. Aesthetic dentures and their phonetic values. J Prosthet Dent 1951; 1: 98.
- 5- Kazanoglu A, Unger JW. Determining the occlusal plane with the Camper's plane indicator. J Prosthet Dent 1992; 67: 499-501.
- 6- Husseinovitch I, Chidiac JJ. A modified occlusal plane device. J Prosthet Dent 2002; 87: 240.
- 7- Nayar S. A simple technique for marking the ala-tragal line. J Prosthet Dent 2005; 94: 304.
- 8- Zepa I, Huggare J. Reference structures for assessment of frontal head posture. European Journal of Orthodontics 1998; 20: 694-699.
- 9- Namano S, Behrend DA, Harcourt JK, Wilson PR. Angular asymmetries of the human face. Int J Prosthodont 2000; 13(1): 41-46.
- 10- Thomas GB, Finney RL. Calculus and Analytic Geometry. 7th ed. USA: Addison Wesley; 1988, pp. 8.



**Figure (1)**



**Figure (2)**

**Table (1)** Paired-Sample T Test and the measuring unit is radian (SI unit).

	Mean	Std. Dev.	t	df	P value
<b>PT-ET</b>	<b>.000233</b>	<b>.004461</b>	<b>.286</b>	<b>29</b>	<b>.777</b>

P>.05 (insignificant), P<.05 (significant), and P<.01 (highly significant)