



Size and Morphology of Sella Turcica in Iraqi Adults

Dr. Yassir A. Yassir, B.D.S., M.Sc. (Ortho.)

Dr. Mohammed Nahidh, B.D.S., M.Sc. (Ortho.)

Dr. Hadeel A. Yousif, B.D.S., M.Sc. (Ortho.)

Abstract

To measure the size and describe the morphology of sella turcica on true lateral cephalometric radiographs; and to determine if there is any statistical significant difference in the size of sella turcica regarding the genders and skeletal classes.

The sample included 130 pretreatment digital lateral cephalometric radiographs (67 female and 63 males) with an age range between 17-25 years, collected from the Orthodontic Department in the College of Dentistry, University of Baghdad. The sample was divided according to ANB angle into 3 skeletal classes. The size of sella turcica (length, depth, and diameter) was measured and its morphology was determined. Frequency distribution and percentage described the morphology, independent samples t-test was used to test genders difference, while ANOVA test was performed to show if there is any statistical significant difference in the size of sella turcica among the skeletal patterns.

Males had slightly higher sella turcica measurements than females with a non-significant difference between genders; on the other hand, class III sample had higher sella turcica measurements with a non-significant difference among the skeletal classes. In addition to the normal morphology, six distinct variations of sella turcica were identified with the highest percentage to the normal morphology.

All the linear measurements of the sella turcica were within standard range. Neither gender nor skeletal patterns showed significant differences in sella turcica linear measurements. Normal morphology of the sella turcica was found in the majority of subjects.

Key words: sella turcica, size, morphology.

Introduction

The sella turcica is an important anatomical structure for cephalometric assessment because of its central landmark, sella; a saddle-shaped area of bone located in the middle cranial fossa and houses the body of the pituitary gland. The sella turcica lies on the intracranial surface of the body of the sphenoid and consists of a central pituitary fossa bounded

anteriorly by the tuberculum sellae and posteriorly by the dorsum sellae. Two anterior and two posterior clinoid processes project over the pituitary fossa.¹

Clinicians should be familiar with the normal radiographic anatomy and morphologic variability of this area, in order to recognize and investigate deviations that may reflect pathological situations, even before these become clinically apparent.²⁻⁴ There is an

increasing interest in the study of human craniofacial dysmorphology, but there are only few cephalometric standards available on normal growth and development of the sella turcica.^{5,6} Sella turcica size varies from 5 to 16 mm in anteroposterior diameter and from 4 to 12 mm in vertical depth.^{1,5-9} Changes in size of the sella turcica are frequently related to pathology and syndromes.¹⁰⁻¹⁸ Most of these conditions are not immediately life threatening but some can lead to pituitary apoplexy (necrosis and hemorrhage), which requires urgent management.¹⁹ Studies of the sella turcica size on radiographs have been based either on linear measurement^{5,7,9,19-22}, area measurement^{1,5,19,23-26}, volume measurement^{8,27-29}, or perimeter of the sella turcica.¹

In order to determine if the sella region presents with any unusual appearance, one must study the normal morphology of the sella turcica. In previous studies, the morphology of the sella was described subjectively and qualitatively, and variations were categorized into different types such as circular, oval, flat, shallow, and J-shaped.^{6,7} Regional assessment of sella has identified the following morphological variants: oblique anterior wall, sella turcica bridge, double contour of the floor, irregularities of the posterior part of the dorsum sella, and pyramidal shape of the dorsum sella.⁹ The shape of the sella may also be affected by pathological conditions, such as Down syndrome³⁰, Williams syndrome¹⁶, Seckel syndrome³¹, and lumbosacral myelomeningocele³².

The purposes of the present study were; to describe the morphology and measure the size of sella turcica on true lateral cephalometric radiographs; and to determine if there is any statistical significant difference in the size of

sella turcica regarding the genders and skeletal classes.

Materials and Methods

Sample

The sample of the present study included 130 pretreatment digital true lateral cephalometric radiographs (67 females and 63 males) which had been collected from the files of the patients attending the Orthodontic Department in the College of Dentistry, University of Baghdad. All subjects were Iraqi Arabs in origin, having complete permanent dentition regardless the third molars. The age ranged between 17-25 years. They were clinically healthy with no syndromes, cleft lip and palate, or other facial malformations. No history of previous orthodontic, orthopedic or surgical treatment was recorded.

The sample categorized by the subjects' skeletal Class and then by gender, the sagittal skeletal classification done according to ANB angle into 3 skeletal classes.³³⁻³⁵

Skeletal CI I: $2^{\circ} \leq \text{ANB} \leq 4^{\circ}$.

Skeletal C II: $\text{ANB} > 4^{\circ}$.

Skeletal CI III: $\text{ANB} < 2^{\circ}$.

Accordingly the radiographs were distributed into; 50 class I (27 females and 23 males), 50 class II (25 females and 25 males), and 30 class III (15 females and 15 males).

Method

Size of sella turcica

The linear measurements: length, depth, and diameter of sella turcica were measured (after magnification correction by AutoCAD 2007 computer program) according to **Silverman**⁵, all reference lines used are situated in the midsagittal plane (fig. 1).

§ **The length of sella turcica:** was measured as the distance from the dorsum sellae (Sp) to the tuberculum sellae (TS).

§ **The depth of sella turcica:** was measured as a perpendicular from the line above to the deepest point on the floor of the fossa (Si).

§ **The anteroposterior greatest diameter of the sella turcica:** was measured from the tuberculum sellae (TS) to the remote point on the posterior inner wall of the fossa.

Shape of sella turcica

For the assessment of the morphological aberrations of the sella turcica (after enlargement of its view), the different morphological appearance of the sella turcica described by Axelsson et al^{9, 16}, in addition to the normal morphology of sella turcica were used to be compared with those in the current study. The six morphological variations that rated as normal included oblique anterior wall, sella turcica bridging, double contour of the floor, irregularity (notching) in the posterior part of the dorsum sellae, extremely low sella turcica, and pyramidal shape of the dorsum sellae (fig. 2).

Statistical analyses

All the data of the sample were subjected to computerized statistical analysis using SPSS version 15 (2006) computer program. The statistical analysis included:

§ *Descriptive statistics including:* mean, standard deviation, minimum, maximum and frequency distribution.

§ *Independent-samples t-test:* for the comparison of the size of sella turcica between genders.

§ *One-way ANOVA test:* for the comparison of the size of sella turcica among the skeletal classes.

P < 0.05 considered as statistically significant.

Results and Discussion

In this study the morphological appearance and linear dimensions of the sella turcica in a healthy Iraqi adults males and females with different skeletal patterns were investigated.

By comparing the linear measurements achieved in this study: length, depth, and diameter of the sella turcica (table 1) with other investigations^{9, 22}, a difference between measurements was noted. The mean values for all measured variables in the present study were shown to be larger than those demonstrated by Axelsson et al⁹ in a Norwegian sample by 0.2-1 mm and smaller by 0.5-1.6 mm than those reported by Alkofide²² in a Saudi sample. In the current study it was found that the range of sella turcica depth was 4.83-11.65 mm, and that of antero-posterior diameter was 9.57-16.16 mm, both were within standard ranges.^{2, 38, 39}

Independent sample t-test was used to assess the differences between genders in each skeletal pattern (table 1). There were statistically non-significant differences between males and females regarding the length, depth and diameter of the sella turcica in any of the skeletal pattern, however, generally males had slightly higher measurements than females except for the sella turcica depth in class II females which was slightly higher than males. The non-significant differences of sella turcica length, depth and diameter between genders also detected by Alkofide²². Silverman⁵ reported that the sella turcica in males tends to be larger than that in females from about one year of age until about

thirteen years when the pre-adolescent acceleration of growth in females which began 2 years earlier carries the females to, and subsequently beyond, the males, in males the acceleration occurs about 2 to 3 years later than in females, it is less pronounced, but may persist longer. In 1983 Chilton et al⁸ reported that the volume of the sella turcica in males, as calculated from cephalometric radiographs, was found to be larger than in females; however their study based on measuring the volume of sella turcica and not sella turcica linear dimensions as in the present study. The result of the current study was in part verified by Axelsson et al⁹ who reported that no differences between males and females were detected for the depth and diameter of the sella turcica, while, the length was larger in males and reached significant difference at some age groups, but it differed from those reported by Francis⁴⁰ who found that the size of the sella turcica in female was greater than in males, and Haas²⁴ who compared the mean size in square millimeters of the sella area of boys and girls aged 3-17 years and found some differences due to gender, and reported that the sella turcica of boys was greater than girls, but after 17 years of age, the sella of females were slightly larger than that of males. This differences may arise as those studies examined wide range of age group including childhood and puberty while in this study only adult subjects (17-25 years) were examined, adding to that the great differences between the various measurements are probably due to the use of different landmarks, or measuring techniques.

Few studies have compared the skeletal type of individuals with their sella turcica size to determine if a relationship exists. In this study all linear measurements were higher in total CI III sample than that of total CI

I and CI II; however ANOVA test revealed non-significant difference among the skeletal classes for all variables measured (table 1). This may come in accordance with Preston²⁵ who showed no statistically significant correlation between facial convexity, as measured by the ANB angle and the Wits analysis, and the size of pituitary fossa. There is an agreement with Alkofide²² in that all the measurements were higher in CI III sample but in contrast to her in the diameter when she found a significant difference in sella diameter between class II and III.

Investigations concerning the sella turcica have not only focused on size, but also on morphology. In addition to the normal sella turcica, six distinct morphological types were found, table 2 showed the frequency distribution and percentage of the morphology of sella turcica in genders, different skeletal classes, and the whole sample. Normal anatomical variation of the sella turcica must be considered, as it may vary greatly in normal adult individuals.^{7, 20} Previous studies have used various descriptive terms to evaluate sella shape, and have presented examples of shape aberrations.^{6, 7, 9} It is interesting to note that Axelsson et al⁹ attributed 'normal' sella shape to less than 70 per cent of the sample, even though individuals with no clinically apparent pathology were investigated. It is believed that the remaining 30 per cent should not be considered dysmorphological, but within the normal variability of the population. In this study, the percentage of the normal shaped sella turcica appeared to be higher in females (80.6%) than in males (71.4%), this finding disagrees with Axelsson et al⁹ who found that 65% of females and 71% of males had normal sella turcica shape, interestingly the percentage of the normal shape sella turcica in males subjects were almost

the same in both studies. Again this may attributed to the wide range of age including childhood and puberty for the examined subjects in those studies, sample number and racial factor. Double contour of the floor was more common in the female group, while irregularity (notching) in the posterior part of the dorsum sellae was more common in the male group.

Total CI II and CI III sample showed the highest percentage of normal sella turcica (80%). All six morphological variation of sella turcica were found in CI II, while CI I involved five variations and only four variations found in CI III sample. It has been shown that double contour of the floor was more common in the class I and class III groups, and that irregularity (notching) in the posterior part of the dorsum sellae has shown in 6% of both class I and class II groups, and it was the most common aberration in the class II group.

For the total sample, 71.15% had normal morphology of sella turcica, Alkofide²² reported lower percentage than ours (66.7 %). In comparison with the latter for the other shapes in the total sample, our percentages were less than of her in all other shapes. The presence of a sella turcica bridge in normal individuals is not uncommon and has been shown to occur in 5.5-22 % of subjects^{7, 9, 41, 42}, while in this study it has been shown in 1.6 % of males and didn't show at all in female subjects, this come in part in accordance with Alkofide²² who reported only two cases (1.1%) of the total sample.

Conclusions

1-All the linear measurements of the sella turcica were within standard range.

- 2-Neither gender nor skeletal patterns showed significant differences in sella turcica linear measurements.
- 3-Normal morphology of the sella turcica was found in the majority of subjects.
- 4-Six morphological variations of normal sella turcica were found.

References

- 1- **Jones RM, Faqir A, Millett DT, Moos KF, McHugh S.** Bridging and dimensions of sella turcica in subjects treated by surgical-orthodontic means or orthodontics only. *Angle Orthod* 2005; 75(5): 714-8.
- 2- **Friedland B, Meazzini C.** Incidental finding of an enlarged sella turcica on a lateral cephalogram. *Am J Orthod Dentofac Orthop* 1996; 110(5): 508-12.
- 3- **Feldkamp J, Santen R, Harms E, Aulich A, Mödder U, Scherbaum WA.** Incidentally discovered pituitary lesions: high frequency of macroadenomas and hormone-secreting adenomas-results of a prospective study. *Clinical Endocrinol* 1999; 51: 109-13.
- 4- **Alkofide E.** Pituitary adenoma: a cephalometric finding. *Am J Orthod Dentofac Orthop* 2001; 120(5): 559-62.
- 5- **Silverman FN.** Roentgen standards for size of the pituitary fossa from infancy through adolescence. *Am J Roentgenol* 1957; 78(3): 45-60.
- 6- **Choi WJ, Hwang EH, Lee SR.** The study of shape and size of normal sella turcica in cephalometric radiographs. *Korean J Oral Maxillofac Radiol* 2001; 31(1): 43-9.
- 7- **Camp JD.** The normal and pathological anatomy of the sella turcica as revealed by roentgenograms. *Am J Roentgenol* 1924; 12: 143-56.
- 8- **Chilton LA, Dorst JP, Gam SM.** The volume of the sella turcica in children: new standards. *Am J Roentgenol* 1983; 140(4): 797-801.
- 9- **Axelsson S, Storhaug K, Kjær I.** Post-natal size and morphology of the sella turcica. Longitudinal cephalometric standards for Norwegians between 6 and 21 years of age. *Eur J Orthod* 2004; 26(6): 597-604.
- 10- **Weisberg LA, Zimmerman EA, Frantz AG.** Diagnosis and evaluation of patients with an enlarged sella turcica. *Am J Med* 1976; 61(5): 590-6.

- 11- **Swallow CE, Osborn AG.** Imaging of sella and parasellar disease. *Seminars in Ultrasound, CT, and MRI* 1998; 19(3): 257-71.
- 12- **Dostalova S, Sonka K, Smahel Z, Weiss V, Marek J.** Cephalometric assessment of cranial abnormalities in patients with acromegaly. *J Cranio-Maxillo-Facial Surg* 2003; 31(2): 80-7.
- 13- **Ammar A, Al-Sultan A, Al Mulhim F, Al Hassan AY.** Empty sella syndrome: does it exist in children? *J Neurosurg* 1999; 91(6): 960-3.
- 14- **Sage MR, Blumbergs PC.** Primary empty sella turcica: a radiologicalanatomical correlation. *Aust Radiol* 2000; 44(3): 341-8.
- 15- **De Marinis L, Bonadonna S, Bianchi A, Maira G, Giustina A.** Primary empty sella. *J Clin Endocrinol Metabol* 2005; 90(9): 5471-7.
- 16- **Axelsson S, Storhaug K, Kjær I.** Postnatal size and morphology of the sella turcica in Williams syndrome. *Eur J Orthod* 2004; 26(6): 613-21.
- 17- **Dejager S, Gerber S, Foubert L, Turpin G.** Sheehan's syndrome: differential diagnosis in the acute phase. *J Internal Med* 1998; 244(3): 261-6.
- 18- **Kelestimur F.** Sheehan's syndrome. *Pituitary* 2003; 6(4): 181-8.
- 19- **Andredaki M, Koumantanou A, Dorotheou D, Halazonetis DJ.** A cephalometric morphometric study of the sella turcica. *Eur J Orthod* 2007; 29(5): 449-56.
- 20- **Gordon MB, Bell AL.** A roentgenographic study of the sella turcica in normal children. *New York State J Med* 1922; 22: 54-9.
- 21- **Martin HO.** Sella turcica und Konstitution. Versuch einer Sellagrößen- und Formdeutung innerhalb konstitutionsmedizinischer Gefüge. Leipzig: George Thieme Verlag; 1941. p: 74-84.
- 22- **Alkofide EA.** The shape and size of the sella turcica in skeletal Class I, Class II, and Class III Saudi subjects. *Eur J Orthod* 2007; 29(5): 457-63.
- 23- **Davenport CB, Renfoe O.** Adolescent development of the sella turcica and the frontal sinus based on consecutive roentgenograms. *Am J Roentgenol* 1940; 44(5): 665-79.
- 24- **Haas LL.** The size of the sella turcica by age and sex. *Am J Roentgenol* 1954; 72(5): 754-61.
- 25- **Preston CB.** Pituitary fossa size and facial type. *Am J Orthod* 1979; 75(3): 259-63.
- 26- **Al-Mothaffar NMJ.** Cranial base texture in individuals with prolonged nasal obstruction. *Mustansiria Dent J* 2007; 4(2): 169-73.
- 27- **DiChiro G, Nelson KB.** Volume of the sella turcica. *Am J Roentgenol* 1962; 87: 989-1008.
- 28- **McLachlan MS, Williams ED, Fortt RW, Doyle FH.** Estimation of pituitary gland dimensions from radiographs of the sella turcica. A post-mortem study. *Brit J Radiol* 1968; 41: 323-30.
- 29- **Underwood LE, Radcliffe WB, Guinto FC.** New standards for the assessment of sella turcica volume in children. *Radiol* 1976; 119(3): 651-4.
- 30- **Russell BG, Kjær I.** Postnatal structure of the sella turcica in Down syndrome. *Am J Medical Genetics* 1999; 87(2): 183-8.
- 31- **Kjær I, Hansen N, Becktor KB, Birkebæk N, Balslev T.** Craniofacial morphology, dentition, and skeletal maturity in four siblings with Seckel syndrome. *Cleft Palate-Craniofac J* 2001; 38(6): 645-51.
- 32- **Kjær I, Fischer Hansen B, Reintoft I, Keeling JW.** Pituitary gland and axial skeletal malformations in human fetuses with spina bifida. *Eur J Pediatr Surg* 1999; 9: 354-8.
- 33- **Foster TD.** A textbook of orthodontics. 3rd ed. Oxford: Blackwell Scientific Publication; 1990. p: 95-6.
- 34- **Rani MS.** Synopsis of orthodontics. 1st ed. Delhi: AITBS Publishers Distributors; 1995. p:113.
- 35- **Mitchell L, Carter NE, Doubleday B.** An introduction to orthodontics. 2nd ed. Oxford: Oxford University press; 2004. p: 60.
- 36- **Salzmann JA.** Practice of orthodontics (Volume one). 1st ed. Philadelphia and Montreal: J.B. Lippincott Company; 1966. p: 494.
- 37- **Athanasiou AE.** Orthodontic cephalometry. 1st ed. London: Mosby-Wolfe; 1995. p: 29.
- 38- **Shapiro RS, Janzen AH.** The Normal Skull. New York, NY: Paul B Hoeber; 1960.
- 39- **Paul LW, Juhl JH.** The Essentials of Roentgen Interpretation. Hagerstown, MD: Harper and Row; 1972.
- 40- **Francis CC.** Growth of the human pituitary fossa. *Human Biol* 1948; 20(1): 1-20.
- 41- **Kantor ML, Norton LA.** Normal radiographic anatomy and common anomalies seen in cephalometric films.

- Am J Orthod Dentofac Orthop 1987;
91(5): 414-26.
- 42- **Tetradis S, Kantor ML.** Prevalence of
skeletal and dental anomalies and normal

variants seen in cephalometric and other
radiographs of orthodontic patients. Am J
Orthod Dentofac Orthop 1999; 116(5):
572-7.

Table 1: Descriptive statistics, genders difference, and skeletal classes comparison for sella turcica variables.

Variables	Skeletal Classes										ANOVA test	
		Class I			Class II			Class III			F-test	P-value
	Sex	Male	Female	Total	Male	Female	Total	Male	Female	Total		
Sella length (mm.)	No.	27	23	50	25	25	50	15	15	30	0.192	0.826 (NS)
	Mean	10.107	9.302	9.672	9.878	9.114	9.496	10.179	9.287	9.733		
	S.D.	2.034	1.45	1.771	2.199	1.892	2.066	1.421	1.437	1.476		
	Min	6.4	6.18	6.18	5.55	6.39	5.55	6.68	6.52	6.52		
	Max	13.31	12.43	13.31	16.1	13.86	16.1	12.28	12.04	12.28		
	T-test	-1.627			-1.35			-1.709				
	P-value	0.11 (NS)			0.195 (NS)			0.099 (NS)				
d.f.	48			48			28			129		
Sella depth (mm.)	Mean	8.668	8.208	8.42	8.135	8.34	8.238	8.743	8.592	8.668	1.015	0.365 (NS)
	S.D.	1.235	1.173	1.212	1.38	1.337	1.349	1.661	1.121	1.395		
	Min	6.57	5.36	5.36	4.83	5.98	4.83	5.62	7.63	5.62		
	Max	11.42	10.51	11.42	10.39	11.29	11.29	11.65	11.43	11.65		
	T-test	-1.35			0.535			-0.291				
	P-value	0.183 (NS)			0.595 (NS)			0.773 (NS)				
	d.f.	48			48			28				
Sella diameter (mm.)	Mean	12.301	11.703	11.978	12.41	12.392	12.401	12.713	12.302	12.508	1.819	0.166 (NS)
	S.D.	1.415	0.913	1.197	1.533	1.485	1.494	1.421	1.432	1.417		
	Min	9.57	10.26	9.57	9.61	10.03	9.61	10.54	10.43	10.43		
	Max	15.16	14.17	15.16	15.86	16.16	16.16	15.32	15.6	15.6		
	T-test	-1.801			-0.042			-0.788				
	P-value	0.078 (NS)			0.967 (NS)			0.437 (NS)				
	d.f.	48			48			28				

No.: number, S.D.: standard deviation, Min: minimum, Max: maximum, d.f.: degree of freedom.

Table 2: Frequency distribution and percentage of the shape of sella turcica in different skeletal classes, both genders, and in total sample.

Shape	Classes						Sex				Total sample	
	Class I		Class II		Class III		Males		Females			
	Fi	%	Fi	%	Fi	%	Fi	%	Fi	%	Fi	%
Double	7	14	1	2	3	10	4	6.3	7	10.4	11	8.46
Normal	35	70	40	80	24	80	45	71.4	54	80.6	99	76.15
Notching	3	6	3	6	1	3.3	5	7.9	2	3	7	5.38
Oblique	2	4	2	4	1	3.3	3	4.8	2	3	5	3.84
Pyramidal	2	4	2	4	1	3.3	4	6.3	1	1.5	5	3.84
Low	1	2	1	2	0	0	1	1.6	1	1.5	2	1.53
Bridge	0	0	1	2	0	0	1	1.6	0	0	1	0.76
Total	50	100	50	100	30	100	63	100	67	100	130	100

Fi: frequency distribution, %: percentage.

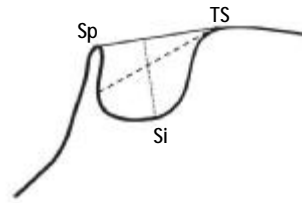


Figure 1: Normal morphology of sella turcica with reference lines used to measure its size: *TS (Tuberculum sellae)*: Anterior boundary of the sella turcica.³⁶ *Sp (Dorsum sellae)*: The most posterior point on the internal contour of the sella turcica.³⁷ *Si (Floor of sella)*: The lowermost (deepest) point on the internal contour of the sella turcica.³⁷

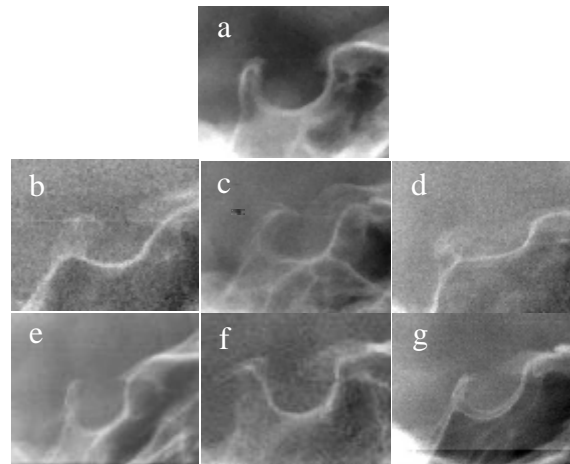


Figure 2: Morphology of sella turcica: a: normal sella turcica, b: oblique anterior wall, c: sella turcica bridging, d: extremely low sella turcica, e: irregularity (notching) in the posterior part of dorsum sellae, f: pyramidal shape of the dorsum sellae, g: double contour of the floor.