



Evaluation the Effect of Different Instrumentation & Obturation Techniques on the Apical Sealing Using Two Types of Sealers

Dr. Hala P. Hanna.

Dr. Raid F. Salman.

Abstract

There is controversy as to which instrumentation &/or obturation techniques to choose with which type of sealer give better apical sealing. This in vitro study aimed to evaluate the apical sealing ability of three obturation techniques and two types of sealer.

A total of 120 teeth were randomly divided into two groups; roots prepared using step-back and hybrid techniques. Each group of instrumented roots were subdivided randomly into three obturation groups of 20 roots for each; each one of these obturation techniques were used twice; once with ZOE sealer and other with AH26 sealer. Then dye penetration study conducted & samples were examined under the stereomicroscope. Data had been collected from two independent examiners and statistically analyzed using student t-test.

Concerning the obturation techniques, warm vertical compaction showed best apical sealing. Regarding sealers, AH 26 sealer had better sealing ability than ZOE sealer with highly significant difference.

Warm vertical compaction obturation technique in combination with the AH 26 resin sealer obturates the canals with lesser apical leakage.

Introduction

The cold lateral compaction of gutta-percha is one of the most commonly used techniques in endodontics. However, its ability to replicate the internal surface of root canal has been questioned¹. Therefore, warm vertical compaction was developed by Schilder to overcome the shortcomings of cold lateral compaction technique; Schilder established that the vertical compaction of warm gutta-percha produces dense, dimensionally stable and three-dimensional root canal fillings, besides the use of warm gutta-percha with vertical compaction permits great density to be created in the apical

portion of the filling². Advances in technology have led to development and implementation of many gutta-percha obturating systems, one of these is Obtura II, which is a thermo-plasticized injectable obturation technique introduced to improve the homogeneity and surface adaptation of the gutta-percha¹. The use of a sealer during root canal obturation is essential for success.

Studies showed that the resin-based root canal sealers presented lesser apical micro-leakage than the zinc oxide-eugenol-based sealer, both in vitro³, and in vivo⁴. This study aimed to evaluate the efficacy of three

obturation techniques; lateral compaction technique, warm vertical compaction technique, and thermo-plasticized gutta-percha technique with using two different types of sealers in relation with the apical sealing of the teeth.

Materials & methods

1. Sample selection

The samples were obtained from freshly extracted teeth. The external tissue debris, calculus, soft tissue and the clotted blood were removed with scalar and tooth brush under running tap water & were collected in a special container containing 50% alcohol solution.

2. Sample preparation

The collected teeth had been subjected to de-coronation process. After that, each root with a single canal would be chosen & checked by a stainless steel k-file (size # 15) to verify the canal patency. The stainless steel k-file (size # 15) must reach the apical terminus & appear from the root apex slightly & tightly (just seen). Any root that was not fulfills this criterion had been discarded and not involved in the study. After that the working length was calculated using stainless steel k-file (size # 15) & the working length determined by kept it 1 mm short of the apex.

3. Sample grouping

The selected roots (120 in no.) were divided randomly into 3 groups; Group A: Roots instrumented with hand step-back technique (60 roots), Group B: Roots instrumented with hybrid technique (60 roots). Then each group was subdivided randomly into 3 subgroups; 1. Roots obturated by cold lateral compaction technique (20 roots), 2. Roots obturated by vertical compaction of warm gutta-percha technique (20 roots). 3. Roots

obturated by injectable thermo-plasticized gutta-percha technique (20 roots). Each group was further subdivided randomly into 2 subgroups; roots obturated with Zinc oxide eugenol sealer (10 roots), & roots obturated with epoxy resin sealer (10 roots).

4. Instrumentation techniques

The step-back instrumentation was started with hand Ni-Ti k-file (#15) which was introduced to the full working length and used in watch-winding action & was repeated for #25, #30, & the Ni-Ti K-file # 35 was considered the master apical file. Flaring of the canal to (#50) & recapitulation was executed then to confirm canal patency. The hybrid instrumentation was started with Gates-Glidden drill no. 1, was used to prepare the coronal two-third of the canals. Then followed by no.2 & no.3, were used to the coronal half of the canal & then no. 4, 5 and 6 were used only at the orifice level. After that, apical third instrumentation was started with hand Ni-Ti K-files & # 35 was considered the master apical file. After each file, the canal was irrigated with 0.2 mm of %17 EDTA for 1 min. combined with 1ml of 5.25% prepared NaOCl to remove the organic and inorganic remnants.

5. Sealer mixing and application

The powder and liquid of the two sealers were mixed on a cold dry clean glass slab using cement mixing spatula according to the manufacturer instructions. The mixed sealer should string out at least an inch when the spatula is lifted from the mix. A finger spreader (size # 35) was used to apply the sealer to the canal.

6. Obturation techniques

The cold lateral compaction technique used in the usual way & the technique was considered

completed when the spreader had no more space to penetrate the canal orifice. For warm vertical compaction technique, the checked master gutta-percha cone was coated with a thin film of sealer and inserted into the canal immediately by tweezers. As soon as possible, heated finger plugger (size # 25) was introduced inside the canals in such away it reached apical third with complete freedom & was used to compact the master gutta-percha cone vertically in an apical direction with sustained pressure until apical resistance to the compaction pressure was felt. A second piece & third piece of gutta-percha cones were cut off at the canal orifice with heated finger plugger (size # 35 & #40). As soon as possible, heated finger plugger (size # 35) was introduced inside the canals in such away it reached the coronal 2/3 & was used to compact gutta-percha vertically in an apical direction. The technique was considered completed when the canal orifice completely filled.

For injectable thermo-plasticized technique, the canals were obturated by injecting thermo-plasticized gutta-percha mass using the bee-fill device via a bee-fill cartridge which was inserted into the canals in three steps. As gutta-percha was injected, the tip felt raised, at this point, the hand was removed from the sensor pad to stop gutta-percha ejection, the tip was removed from the canal and as soon as possible, cold finger pluggers (sizes # 25, # 35, & # 40) were introduced inside the canals in such away they reached (to the coronal two thirds of the canal, to the coronal one third, & to coronal 2-3 mm from the orifice respectively). All the obturated samples were stored at a temperature (37 °C) at a special container.

7. Radiographic evaluation

The obturated samples were left dry aside for 7 days after obturation at a temperature (37 °C) to allow complete setting of the sealer⁵. After that, the samples were radio-graphed in bucco-lingual aspect to evaluate the homogeneity, compaction, adaptation & extension of the obturation. The radiographs were then viewed by two experienced specialists (blinded to the groups) with two readings for each of them with interval of three days, (fig.1).

8. Dye penetration study

With the exception of apical 2mm, the rest of the root surface was covered with three layers of nail polish. After that 2% Methylene blue dye was added. These were left at room temperature (37°C) for 72 hours. After this period, the roots were removed and washed under tap water thoroughly and allowed to dry for 48 hours, at room temperature (37°C). Then each root was marked at the middle of mesial and distal sides with a longitudinal line by a permanent marker, then the roots were cut into two halves buccal and lingual using a diamond cutting disc via slow-speed conventional hand-piece with the aid of chisel. Each half was fixed to microscopic slide by sticky wax to allow its examination under stereomicroscope.

9. Stereomicroscope evaluation

The slides with the samples were examined under the stereomicroscope (2x & 4x) by two experienced specialists (blinded to the groups) with two readings for each of them with interval of three days, (fig.2). However, the criteria for the stereomicroscopic evaluation were as following:

- Score 0: No dye penetration.
- Score 1: 0-1 mm dye penetration.
- Score 2: 1-2 mm dye penetration.

- Score 3: 2-3 mm dye penetration.
- Score 4: >3 mm dye penetration.

Results

1. Radiographic evaluation

By using t- test, there was non-significant difference between the step-back compared with hybrid technique at $p > 0.05$, with in favor of hybrid technique. By using t- test, there was non-significant difference between the lateral compaction compared with warm vertical compaction technique at $p > 0.05$, with in favor of lateral compaction technique. While there was significant difference between the injectable thermo-plasticized techniques compared with the lateral compaction technique at $p < 0.05$, whereas, there was highly significant difference between the injectable thermo-plasticized techniques compared with the warm vertical compaction technique at $p < 0.01$. By using t- test, there was significant difference between the AH26 sealers compared with zinc-oxide eugenol sealer at $p < 0.05$, (fig.4).

2. Stereomicroscopic evaluation

By using t- test, there was highly significant difference between the step-back compared with hybrid technique at $p < 0.01$. By using t- test, there was non-significant difference between all the obturation techniques at $p > 0.05$. By using t- test, there was highly significant difference between the AH26 sealers compared with zinc-oxide eugenol sealer at $p < 0.01$, (table 1&2), (fig.3).

Discussion

While some studies showed that lateral compaction of gutta-percha showed superior radiographic quality

from the bucco-lingual view compared with low-temperature thermo-plasticized gutta-percha (Ultrafil)⁶, and thermo-plasticized gutta-percha (multiphase gutta-percha)⁷. However in both studies the thermo-plasticized gutta-percha technique had better sealing ability than lateral compaction technique. Many studies had support the use of the thermo-plasticized technique and confirm its ability to achieve a detailed replica of cavitations & defects within the root canal system, and a seal equal to that produced by other conventional methods, and a quality root canal fill in a significant shorter period⁸. The cold lateral compaction, in this study, showed better radiographic quality than the warm vertical compaction, and this is one of the disadvantages of cold lateral compaction technique in which the radiographic appearance of the canal filling homogeneity is better than it is in reality⁹. Further, the bucco-lingual view suggested a denser fill than the mesio-distal view. This was not unexpected, because the bucco-lingual width of teeth is usually greater than the mesio-distal width. There is more filling material to absorb x-rays from the buccal aspect than from the proximal side, so on bucco-lingual radiographs the root fillings are more opaque. These results confirm that the radiographs exposed clinically do not relate to proximal views that more accurately reflect the degree of obturation¹⁰.

Many studies confirm the effectiveness of hybrid technique in root canal preparation¹¹. The most important factors that might affect this difference are the spreader penetration & canal form. Thus this difference might attribute to these variables. Authors evaluated the effect of the taper of the preparation on the seal; they found that standardized

preparations showed extensive leakage apically whereas step-back preparations showed little leakage. Micro-leakage usually extended close to the distance of spreader tip penetration. The step-back technique shape the canal in smooth tapered funnel shape in gradual manner that permit deeper spreader penetration which is one of the aims of this preparation, consequently, less leakage might be expected apically¹². Root canal form influenced the short-term sealing ability. In the long-term the seal was affected by the sealer rather than root canal form. The step-back technique might preserve the natural shape of the canal more than the hybrid technique & the use of the aggressive pre-enlargement of the Gates-Glidden drills; this might affect the canal form which has influence on the sealing ability¹³.

The lateral compaction produces a less homogeneous obturation with poorer adaptation to the canal walls compared the techniques that use thermo-plasticized gutta-percha¹⁴. As well others agreed with these results, & this may explained by the superior flow properties of heated gutta-percha and the movement of material into canal irregularities, such as apical deltas and accessory canals^{6, 15}.

The results of the present study can be explained by the following previous findings of their researchers:

1. When warm vertical compaction technique used in vitro, it created more complete obturation at the 2 and 4 mm levels than cold lateral compaction¹⁶.
2. Penetration of root canal sealers into the dentinal tubules could improve sealing of the root canal system by increasing the surface area contact of filling materials to dentinal walls; filling technique may influence the ability of dentinal tubule penetration of

endodontic sealer. Vertical compaction of warm gutta-percha showed a deeper tubule penetration than cold techniques¹⁷.

3. Warm vertical compaction produced significantly higher gutta-percha adaptation than lateral compaction in oval-shaped canals, which are common in the apical third and may affect sealing of the canal¹⁸.
4. Deeper heat penetration during warm vertical compaction of gutta-percha improved the three-dimensional obturation of the root canal space¹⁹.
5. Lateral compaction developed little homogeneous mass and the final filling consists of a large number of separated gutta-percha cones tightly pressed together and joined by frictional grip and the cementing substance only & the use of warm gutta-percha with vertical compaction allows the filling of accessory canals and foramina and permits great density to be created in the apical portion of the filling².

In the present study, the AH26 sealer showed better sealing ability than ZOE (Dorifill) sealer, with highly significant difference. Many studies agreed with this^{20,21}. These findings may possibly be attributed to the fact that the resin-based sealers have resin components in their formulations, which improve their adherence to the intra-canal dentin walls and is an important factor for leakage prevention²¹. The epoxy resin-based AH26 is thought to be able to react with any exposed amino groups in collagen to form covalent bonds between the resin and collagen when the epoxide rings opens²¹.

Conclusions

The roots prepared with step-back technique had a better apical sealing than those prepared with hybrid technique with highly significant difference. The warm vertical compaction gave the best apical sealing followed by injectable thermo-plasticized gutta-percha, which in turn better than cold lateral condensation. Sealer based on epoxy resin (AH 26) sealed roots better than Zinc oxide based sealer.

References

- 1- Rajeswari P., Gopikrishna V., Parameswaran A., Gupta T. & Kandaswamy D. In-vitro evaluation of apical micro-leakage of thermafil and obtura ii heated gutta-percha in comparison with cold lateral condensation using fluid filtration system. *Endodontology* 2005; 17(2):24-31.
- 2- Schilder H. Filling Root Canals in Three Dimensions. *J Endod.* 2006; 32(4):281-90.
- 3- Dultra F., Barroso J., Carrasco L., Capelli A., Guerisoli D. & Pécora J. Evaluation of apical micro-leakage of teeth sealed with four different root canal sealers. *J Appl Oral Sci.* 2006; 14(5):341-5.
- 4- Kopper P., Vanni J., Della Bona A., Figueiredo J. & Portos. In vivo evaluation of the sealing ability of two endodontic sealers in root canals exposed to the oral environment for 45 and 90 days. *J Appl Oral Sci.* 2006; 14(1):43-8.
- 5- Allan N., Walton R. & Schaffer M. Setting times for endodontic sealers under clinical usage and in vitro conditions. *J Endod.* 2001; 27(6):421-3.
- 6- Al-Dewani N., Hayes S. & Dummer P. Comparison of laterally condensed and low-temperature thermo-plasticized gutta-percha root fillings. *J Endod.* 2000; 26(12):733-8.
- 7- Gilhooly R., Hayes S., Bryant S. & Dummer P. Comparison of cold lateral condensation and a warm multiphase gutta-percha technique for obturating curved root canals. *Int Endod J.* 2000; 33: 415-20.
- 8- Glickman G. Injectable thermo-plasticized gutta-percha systems. *Pract Proced Aesthet Dent.* 2001; 13(6):477-82.
- 9- Devčić N., Miletić I., Pezelj-Ribarić S. & Šegović S. micro-leakage of different root canal obturation techniques. *Acta Stomatol Croat.* 2005; 39(1):81-4.
- 10- Kersten H., Wesselink P. & Thoden van Velzen K. The diagnostic reliability of the buccal radiograph after root canal filling. *Int Endod J.* 1987; 20: 20-4.
- 11- Saunders W. & Saunders E. Effect of non-cutting tipped instruments on the quality of root canal preparation using a modified double-flared technique. *J Endod.* 1992; 18(1):32-6. Abs.
- 12- Allison D., Weber C. & Walton R. The influence of the method of canal preparation on the quality of apical and coronal obturation. *J Endod.* 1979; 5(10):298-304.
- 13- Juhász A., Verdes E., Tóké L., Kóbor A. & Dobó-Nagy C. The influence of root canal shape on the sealing ability of two root canal sealers. *Int Endod J.* 2006; 39(4):282-6.
- 14- Brosco V., Bernardineli N. & Moraes I. In vitro evaluation of the apical sealing of root canals obturated with different techniques. *J Appl Oral Sci.* 2003; 11(3): 181-5.
- 15- Ibarrola J., Reynolds R., Hermsen M., Howard J. & Knowles K. Evaluation of three methods of obturation using the obtura II system. *Braz J Oral Sci.* 2002; 1(3):126-128.
- 16- Jarrett S., Marx D., Covey D., Karmazin M., Lavin M. & Gound T. Percentage of canals filled in apical cross sections – an in vitro study of seven obturation techniques. *Int Endod J.* 2004; 37: 392-8.
- 17- Deus G., Murad C., Reis C., Gurgel-Filho E. & Coutinho Filho T. Analysis of the sealing ability of different obturation techniques in oval-shaped canals: a study using a bacterial leakage model. *Braz Oral Res* 2006; 20(1):64-9.
- 18- Iqbal M. & Ku J. Instrumentation and obturation of the apical third of root canals: addressing the forgotten dimension. *Compendium of Continuing Education in Dentistry.* 2007; 28(6): 314-21.
- 19- Smith R., Weller R., Loushine R. & Kimbrough W. Effect of varying the depth of heat application on the adaptability of gutta-percha during warm vertical compaction. *J Endod.* 2000; 26(11): 68-72.
- 20- Limkangwalmongkol S., Burtscher P., Abbott P., Sandler A. & Bishop B. A comparative study of the apical leakage of four root canal sealers and laterally condensed gutta-percha. *J Endod.* 1991; 17(10):495-9. Abs.

21- Suprabha B., Sudha P. & Vidya M. A
comparative evaluation of sealing ability

of root canal sealers. Indian J Dent Res.
2002; 13(1):31-6.

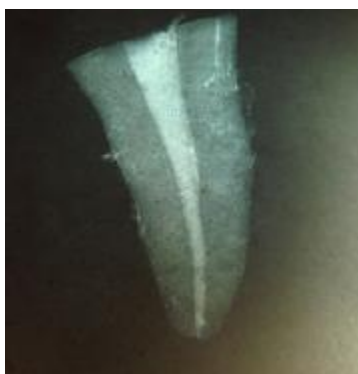

Fig.1: Radiographic evaluation



Fig.2: Score 3- Stereomicroscopic evaluation

Table 1: The descriptive statistic of the variables

variables	No. of samples	Mean	SD
Step-back	40	1.0041	± 0.4
Hybrid	40	1.1916	± 0.5
VCT	160	1.037	± 0.5
ITT	160	1.1	± 0.5
LCT	160	1.156	± 0.6
AH26	40	1.033	± 0.5
ZOE	40	1.16	± 0.5

Table 2: t-test for difference between the variables

variables	df	t-statistic	P-value	Sign.
Step-back – Hybrid	459	-3.8	0.000	HS
VCT - LCT	306	-1.9	0.05	NS
ITT- LCT	310	-0.8	0.3	NS
VCT - ITT	318	-1.09	0.2	NS
AH26 – ZOE	478	-2.6	0.009	HS

Fig. 3: Bar chart showing the three variables (stereomicroscopic evaluation)

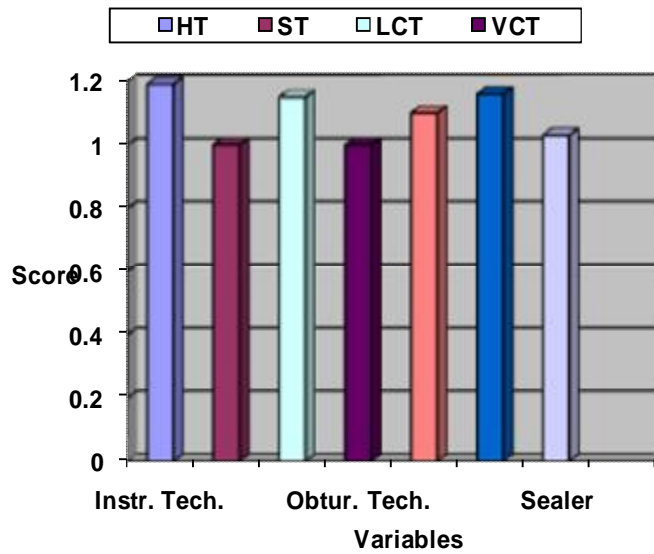


Fig. 4: Bar chart showing the three variables (radiographic evaluation)

