



## Horizontal and Vertical Position of the Mental Foramen on Panoramic Views of a Selected Iraqi Population

**Dr. Salah J. Muhsen, B.D.S.,M.Sc.**

### Abstract

The mental foramen is the opening of the short mental canal, through which the mental nerve the terminal branch of the inferior alveolar nerve exits, knowing the exact position of the mental foramen is essential in oral surgical procedures. This study determines this position in a selected Iraqi population.

240 panoramic radiographs of Iraqi population selected from three different oral and maxillofacial centers to identify the normal range of position of the mental foramen, both horizontal and vertical position were studied, radiographs with any errors or taken for patients not co inside with our criteria were excluded.

In horizontal position , 51.31% were found apical to the lower second premolar , 43.64% between the first and second premolars, 3.07% were found between second premolar and lower first molar, 1.09% were found apical to the lower first premolar, 0.87% were found between lower canine and lower first premolar.

In vertical position,60.08% were found inferior to the apex of the related tooth, 36.84% were found within the apex of the related tooth while 3.07% were found superior to the apex.

The mental foramen can be found anywhere from lower canine to the lower first molar, although 94.95% of the studied radiographs showed that mental foramen was located either between the lower premolars or at the apex of the second premolar.

**Key words: mental foramen, position, panoramic radiographs, Iraqi population.**

### Introduction

The mental foramen is defined as entire funnel like opening in the lateral surface of mandible at the terminus of the mental canal<sup>(1)</sup>, the location of the mental foramen varies among anatomical investigations, some text books of anatomy report it located between premolars<sup>(2,3,4)</sup>, others reported under the second premolar<sup>(5,6)</sup>, and still others state that it can be located in either place<sup>(7,8)</sup> Knowledge of the position of mental foramen is important both when administering

regional anesthesia , performing periapical surgery , dental implant surgery and endodontic treatments in the mandible .Although it is often possible to identify the mental foramen radiographically and by palpation, knowledge of the normal range of possible location is essential<sup>(9)</sup>. The extra oral panoramic radiograph has gained popularity in the last four decades, the advantages of this technique over intra oral radiograph include a great area of hard and soft

tissue coverage, continuity of the visualized area, and rapidity with which the view is formed. The ability to view entire body of the mandible should allow a more accurate location of the mental foramen in both a horizontal and vertical dimensions.<sup>(1)</sup>

According to Yousue and Brooks<sup>(10)</sup>, the mental canal has been classified into four types:

**Type I:** the mental canal is continuous with the mandibular canal.

**Type II:** the mental canal is distinctly separated from mandibular canal.

**Type III:** the mental canal is diffused with a distinct border of the foramen.

**Type IV:** unidentified group.

Also the average size of the foramen is 4.6mm horizontally and 3.4mm vertically on the lateral surface of the mandible, the foramen is usually larger in the left side of the mandible.

## Materials and Method

In this retrospective study, 240 orthopantomographs (O.P.G) gathered from three oral and maxillofacial centers at the college of dentistry, specialized surgeries hospital and Al-wastti hospital, all these views were taken by dimax3 digital x-ray machine manufactured by Planmeca OY, Helsinki, Finland. The magnification factor reported by the manufacturers was 1.25, the radiographs were chosen according to the following criteria:

1. High quality with respect to angulations, contrast and processing artifacts.
2. All mandibular teeth from the right 1<sup>st</sup> molar to left 1<sup>st</sup> molar were present to avoid the possibility of drifting of the teeth towards the missing tooth space.
3. The film must be free from any radiolucent or radiopaque lesion in the lower arch.
4. Radiographs in which lower premolars were missing or had deep

caries, root canal treatment or various restoration were eliminated because of a possible associated pathology causing aperiapical radiolucency.

5. Radiographs in which the upper premolars were missing were eliminated because of the possibility of over eruption of the lower premolars.

The position of the mental foramen on the radiograph was recorded according to the categories listed by Aljasser and Nwoku<sup>(11)</sup>

**Position 1:** the foramen situated anterior to the 1<sup>st</sup> premolar.

**Position 2:** the foramen situated in line with the 1<sup>st</sup> premolar.

**Position 3:** the foramen situated between the 1<sup>st</sup> and 2<sup>nd</sup> premolar.

**Position 4:** the foramen situated in line with 2<sup>nd</sup> premolar.

**Position 5:** the foramen situated between the 2<sup>nd</sup> premolar and 1<sup>st</sup> molar

**Position 6:** the foramen situated in line with the 1<sup>st</sup> molar.

With the use of calibrated grid, the location of the mental foramen was measured separately in relation to the long axis of the teeth to obtain the horizontal position, while in vertical plane; it was registered as superior, inferior, or overlapping the apex of the related tooth.

## Results

The appearance and location of mental foramen were observed on panoramic radiographs of 228 patients from 240 radiographs examined (95%), the (12) undistinguished radiographs (5%) were excluded from the study, of 228 patient, 101 (44.3%) were male and 127 (55.7%) were female, the mean age of the patient was (23.95) years, the youngest patient was (13) years old and the oldest was (70) years old. The most common horizontal position for the mental foramen

relative to the teeth in this sample was in the line with second premolar (position 4), for both the right and left side (n=234, 51.31%). The second most common position was between the first and the second premolar (position 3), (n=199, 43.64%). The third position was between the second premolar and first molar (position 5), (n=14, 3.07%). The fourth position was in line with first premolar (position 2), (n=5, 1.09%). The fifth position was between first premolar and canine (position 1), (n=4, 0.87%). No case was recorded in position 6. In the vertical position records, the most common position was position I (inferior to the apex of the related tooth), (n=274, 60.08%). The second position was position II (within the apex of the related tooth), (n=168, 36.84%). The third position was position III (superior to the apex of the related tooth), (n=14, 3.07%).

## Discussion

The use of panoramic radiograph gives a survey of the whole maxillary and mandibular dento-alveolar area on a single film. The use of this technique has been indicated for screening and diagnosis of pathological lesions, studying and evaluation of pathological anomalies, treatment planning, and as apart of follow up in cases of survey<sup>(12)</sup>. Of 240 panoramic radiograph, 12 (5%) the mental foramen could not be identified, so these radiographs were excluded from the study sample. The reason of inability to identify the mental foramen could be due to the thickness of the lingual cortical plate of the mandible or due to the trabecular pattern which effects the appearance of the foramen in the area of examination. This (5%) of un identified mental foramen is less than that found by lazem, A.I and A. fattah, A<sup>(13)</sup> and Bavitz et al<sup>(14)</sup> who

stated that unidentified mental foramen ratio were 5.5% and 20.4% respectively on panoramic radiograph. The reason of our smaller ratio in our study could be because we studied the views on computer screen where we can manipulate the view like the contrast and size as we need to find the exact position of the foramen, while the other two studies used a radiograph sheets in their studies which may be exposed to processing problems. Also in comparison between aperiapical and panoramic radiograph, in aperiapical view mental foramen could be seen in only 47% as stated by Fishel et al,<sup>(15)</sup> and sweet<sup>(16)</sup> who reported that the ratio was 55% of aperiapical view, this findings is much more smaller if compared with our results on panoramic radiograph (95%), the difference is clearly due to a small size of aperiapical film and large size of panoramic film that covers the whole mandible.

In the analysis of the 288 panoramic radiographs in this study, regarding horizontal position, it was found that the mental foramen was positioned anywhere between the long axis of the canine to that of the mesiobuccal root of the first molar. This agrees with the findings of the other researcher<sup>(9,11,15)</sup>. However, the most common position was in line with the longitudinal axis of the second premolar (position 4) (n.234, 51.3%), followed by the position 3 between first and second premolars (n199, 43.6%) ; with these two positions making an overall prevalence of 94.9%. This is in agreement with other studies<sup>(9,11,17)</sup>, while in a study of selected Baghdad subjects, abduhaleem<sup>(18)</sup> in 2004 found that position 3 was the most common position (56.5%), followed by position 4 (34.3%) but if we collect the previous two positions (90.8%) it seems close to our results (94.9%), but

we agree with him in the rest of the positions, position 5 (6.4%), position 2 (2.8%) which was (3.07%), (1.09) respectively in our study. Some investigators claimed that there is clear racial trend in the anterior posterior position of the mental foramen, it being more anterior in the Caucasoid groups.<sup>(17)</sup>

In vertical position estimation, we found that mental foramen is most commonly found in position I (inferior to the level of tooth apex) which represent 60.8%, while 36.84% were present in position II (within the apex level of the tooth) and lastly in position III (superior to the level of tooth apex) having only 3.07%, these findings disagree with Fishel et al<sup>(15)</sup> who found vertical position 24.5% in position I, 13.9% in position II, 61.6% in position III. While other researchers measured the vertical position according to Yosue and Brooks<sup>(10)</sup>, by drawing a vertical line from the upper most border of the alveolar bone to the lower most border of the mandible passing through the center of the mental foramen and gave a ratio of the bone above the mental foramen to that below it, so we could not compare our result to that gathered by this method.

## References

- 1- Phillips JL, Weller RN, Kulild JC (1992) the mental foramen: 2 radiographic position in relation to the mandibular second premolar. J endod 18,271-274.
- 2- Grant, J.C.B. ,and Basamdjian, J.V : Grant`s method of anatomy , ed.7Baltimore, 1965, William`s and Wilkins compony, p.630 .
- 3- Breathnach ,A.S. :frazer`s anatomy of the human skeleton, ed.6, London ,1965, J. and A.Churchill, Ltd.,p.233 .
- 4- Last, R.J.: anatomy –regional and applied, ed.5,London ,1972.Churchill livingstone, p.884 .
- 5- Gross, C.M.: gray`s anatomy, ed.27, Philadelphia, 1963, lea and Febiger, p.180.
- 6- Crouch, J.E.: functional human anatomy, ed.2, Philadelphia 1973, lea and febiger , p.13 .
- 7- Sicher ,H, and dubrul , E.L. :oral anatomy,ed.9,St.louis,1970, the C.V. Mosby company,p.421 .
- 8- Tebo , H.G., : Cunningham`s text book of anatomy, ed.9, London, 1951, oxford university press, p.201 .
- 9- Moiseiwitsch, J.R., Oral surg. Oral pathol. Oral radiol. Endo d., 89 (1998) 457.
- 10- Yosue,T Brook, SL (1989): The appearance of the mental foramen on the panoramic radiographs .II. Experimental evaluation. Oral Surg. Oral Med. Oral pathol. 68,488-492.
- 11- Al-jasser NM, Nwoka AL (1998): radiographic study of the mental foramen in selected Sau population. Dento maxillofacial radiol 27, 341-343.
- 12- Stafen ,C. and Gibilso, J.A. (1985): Oral radiographic diagnosis. 5<sup>th</sup> ed., Philadelphia, Saunders Co.
- 13- Lazem, A.I A.Fattah, A (2006): An analysis of digital panoramic radiographs for shape, appearance and position of mental foramen. M.Sc thesis, college of dentistry, Baghdad university.
- 14- Bavitz, J.B. etal (1993): An anatomical study of mental neurovascular bundle – implant relationship. International journal of oral and maxillofacial implants. 8(5):563-567.
- 15- Fishel, D.etal .(1976): Roentgenologic study of the mental foramen. Oral Surg Oral Med Oral Pathol 41, 682-686.
- 16- Sweet, A.P.S. (1959): Radiodontic study of the mental foramen, dent radiograph. Photogr. 32: 28-33.
- 17- Green, R.M (1987): The position of the mental foramen,: comparison between the southern (Hong Kong) Chinese and other ethnic and racial groups. Oral Surg Oral Med Oral Pathol 63. 278-290.
- 18- Abdulhaleem, S.H(2004) : The shape , appearance and position of the mental foramen on panoramic radiograph in a selected Baghdadi subjects. M.Sc thesis , college of dentistry, university of Baghdad.

Table 1. location of the mental foramen in the horizontal plane.

Location of the mental foramen	No. of the mental foramen on the right side		No. of the mental foramen on the left side		Total No. of the mental foramen (both side)	
	No.	%	No.	%	No.	%
Position 1	2	0.87%	2	0.87%	4	0.87%
Position 2	1	0.44%	4	1.75%	5	1.09%
Position 3	98	42.98%	101	44.29%	199	43.64%
Position 4	122	53.50%	112	49.12%	234	51.31%
Position 5	5	2.19%	9	3.94%	14	3.07%
Position 6	0	0%	0	0%	0	0%
<b>Total</b>	<b>228</b>	<b>100%</b>	<b>228</b>	<b>100%</b>	<b>456</b>	<b>100%</b>

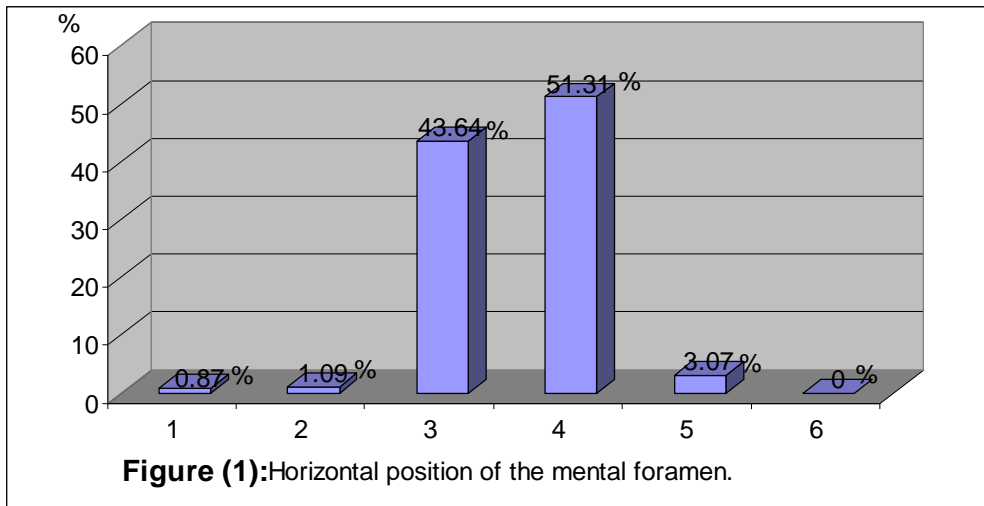


Table 2. location of the mental foramen in the vertical plane.

Location of the mental foramen	No. of the mental foramen on the right side		No. of the mental foramen on the left side		Total No. of the mental foramen (both side)	
	No.	%	No.	%	No.	%
Position I	136	59.64%	138	60.52%	274	60.08%
Position II	85	37.28%	83	36.40%	168	36.84%
Position III	7	3.07%	7	3.07%	14	3.07%
<b>Total</b>	<b>228</b>	<b>100%</b>	<b>228</b>	<b>100%</b>	<b>456</b>	<b>100%</b>

