



## Cone Beam CT Description of Mental Foramen Variants: A Review

Nuhad A. Hassan<sup>1</sup>, Amal K. Jaloob<sup>2</sup>, Abeer A. Aljoujou<sup>3</sup>

<sup>1</sup>Department of Oral Medicine, College of Dentistry, Mustansiriya University, Baghdad, Iraq. E-mail: [nuhad\\_alshammery@yahoo.com](mailto:nuhad_alshammery@yahoo.com), [nihadalwan@uomustansiriya.edu.iq](mailto:nihadalwan@uomustansiriya.edu.iq), ORCID: <https://orcid.org/0000-0002-5601-0924>.

<sup>2</sup>Department of basic sciences, College of Dentistry, Mustansiriya University, Baghdad, Iraq, E-mail : [dr.amalkadhem@uomustansiriya.edu.iq](mailto:dr.amalkadhem@uomustansiriya.edu.iq), ORCID: <https://orcid.org/0000-0001-5708-0804>.

<sup>3</sup>Department of Oral Medicine, College of Dentistry, Damascus University, Damascus, Syria, E-mail : [abeer79.aljoujou@damascusuniversity.edu.sy](mailto:abeer79.aljoujou@damascusuniversity.edu.sy).

*Received 2/2/2023*

*Accepted in revised form 10/09/2023*

*Published 30/06/2024*

### Abstract

The mental foramen (MF) is a crucial marker for local anesthetic, surgical, and implantology treatments. After passing through the mandibular canal, the inferior alveolar nerve and blood vessels exit the MF as the mental vascular nerve. On radiographs, MF appears as a round or oval area of radiolucency inferiorly to the corpus mandible on the lateral sides (left and right). Consideration must be given to its morphology, location, and anatomical variances to minimize mental nerve harm. The focus of this literature review is to find out whether cone beam CT (CBCT) can accurately evaluate MF anatomy implantation and increase the clinician's understanding of this critical topic. Evidence-based research published between 1987 and 2022 was looked for in the literature using MEDLINE (PubMed), Web of Science, Scopus, the Iraq Virtual Science Library, and manual investigation of more sources. This was done to find articles that might be relevant. Between the two premolars, or apically to the second premolar, was where the MF was located most of the time. Men had larger mental foramina than women did, on average. Males tended to have a longer anterior loop than females. More frequently than panoramic, CBCT correctly identified the anterior loop and accessory MF.

**Keywords:** Mental Foramen, cone beam CT, anatomy, implant, morphology.



## Introduction

The mental foramen (MF) is placed on the lateral aspect of the mandible's body; it denotes where the inferior alveolar nerve and blood vessels exit the mandibular canal in the jaw. The mental bundle nourishes the lower lip, chin, and gingival tissue, with blood flow and sensory innervation<sup>1</sup>. The position and shape of the MF may vary according to variables such as age, gender, ethnic variations, and heredity<sup>2,3</sup>. The MF is one of the most frequent locations of iatrogenic damage during anesthetic induction or surgery. Extraction of premolar and molar root tips, as well as implant placement in the mandibular premolar area, are the most complex surgical procedures owing to the risk of neuro-sensory alterations in the lower lip and chin. If the MF is not adequately recognized and safeguarded, the danger of injury rises<sup>1</sup>.

Cone beam CT (CBCT) is a minimal-dose scanning approach developed for capturing images of the jaws and teeth with a revolving conical or pyramidal x-ray beam with a reciprocal image detector, CBCT can capture data from the whole volume of interest. This information is then utilized to create 2 or 3 dimensional (D) slices<sup>4-9</sup>.

The CBCT provides non-superimposed 3D reconstructions of the oral cavity and distinct slices (axial, sagittal, and coronal) of the region of interest. Establishing quantitatively the MF's position and the existence of the anterior loop (AL) is currently best accomplished with high-resolution CBCT<sup>10,11</sup>.

Prior to the advancement of dental rehabilitation procedures and the development of more precise 3D diagnostic images, researchers were also keenly interested in determining the anatomical variation of MF. However, this concern has gained a

heightened level of significance due to the aforementioned developments in CBCT images<sup>12-14</sup>.

Because of their clinical significance, the morphometric properties of MF are of particular interest. The MF can be damaged during surgical procedures, leading to paresthesia or numbness of the lower lip, and chin, and from the MF to the midline<sup>15,16</sup>. Dental surgeons must precisely define the MF before performing bone augmentation, implant insertion, orthognathic surgery, and osteotomies during periapical surgery.<sup>17-20</sup>. Therefore, the focus of this literature review is to find out whether CBCT can accurately evaluate mental foramen anatomy prior to implantation and increase the clinician's understanding of this critical topic.

## Materials and Methods

Evidence-based research published between 1987 and 2022 was looked for in the literature using MEDLINE (PubMed), Web of Science, Scopus, the Iraq Virtual Science Library, and manual investigation of more sources. This was done to find articles that might be relevant. Review articles on similar topics that had been published before were also looked at to see if they might be relevant. For this, the words mental, cone beam CT, anatomy, implant, and morphology were used as keywords.

Only studies that were written in English and used CBCT images to characterize the MF's anatomical structure and the area around it were included. There were rules about what kinds of studies couldn't be used, such as panoramic studies, case reports, and research on children, and studies that used other kinds of CT. The comparison was based on sex, age, dentate state, and ethnic group.

## Results

The first search yielded 60 papers. Eventually, 30 papers were included in the present review. For a better understanding, the key findings of the radiographic examination of the mental foramen characteristics are presented in the following topics:

In around 150 CBCT scans, Al-Qahtani highlighted that the most widespread form of MF was oval, then round<sup>21</sup>. Similarly, Sheikhi et al. observed that oval pictures accounted for 69.4% of all scans in their research of 180 CBCT images, whereas round ones made up just 30%<sup>22</sup>. Ezoddini-Ardakani et al. mentioned that the most typical orientation of the MF is posterior-superior, and it can be oval or circular in shape<sup>13</sup>.

Previous investigations often used panoramic images, which provide a flat view of a curved structure, suggesting that the imaging method may be to blame for the observed discrepancy. Radiology's CBCT yields a correct angular representation of curved structures, with the ability to reduce discrepancies.

In an investigation by Olasoji et al.<sup>23</sup>, 34 percent of cases had the MF between the first and second premolars, and 24.5 percent had it under the second premolar's apex. Some research suggests that MF often occurs between the first and second premolars<sup>24-28</sup>.

CBCT images from 117 patients in Belarus were chosen at random. Most people's mental foramens were found in the space between their lower premolar roots (57.7%) or in the projection of their lower second premolar root (33.8%). Sixty-five percent of patients had an MF that extended below the tops of their roots. A projection line across the root apex was found to be the location of the foramen in 29.5% of the samples. The MF was found high up on the skull, above the root apex, in

5.6% of people. Most 84.2% of the MF was horizontally elongated ovals. The second most common variant (29.1%) has a canal that began mesially to the MF and then curved backward and upwards to create an anterior loop. So dental treatments in the anterior mandible are more successful and safer when the patient's own MF topography is updated using CBCT<sup>29</sup>.

The average diameter of the MF was observed to range from  $2.08 \pm 0.53$  mm to  $4.44 \pm 1.13$  mm by Pelé et al.<sup>30</sup>. Muinelo-Lorenzo et al., and Goyushov et al. both found that it was typically approximately 3 mm<sup>31,32</sup>. Males had a larger average diameter than females did across the literature; the gender gap might be as large as 0.62 mm<sup>9,28,33-39</sup>, Figures 1,2.

The accessory mental foramen (AMF)

According to research conducted by Bositykh et al.<sup>40</sup> and Sisman et al.<sup>41</sup>, the prevalence of AMFs varied from 2% to 26% among the groups investigated, with a higher incidence among males. The earlier authors typically found 1-2 AMFs per subject<sup>37,42-46</sup>. Fewer than 15% of people are thought to have an accessory MF, according to the majority of studies<sup>13</sup>. Ethnic variations have been shown to affect AMF incidence<sup>6,7,9,12,33,47</sup>.

The anterior loop (AL) of the inferior alveolar nerve

The prevalence of AL varied from 10.4% to 94% between trials, and from 10% to 86% across sides studied<sup>48-51</sup>. Among many investigations, only two had a greater mean AL length in females (both  $0.81 \pm 1.18$  and  $6.5 \pm 1.63$  mm), suggesting that the AL mean is longer in males<sup>33,52</sup>.

Clinical importance of mental foramen anatomy

In local anesthetic administration for mental nerve block, the needle should be directed antero-inferior-medially and between the first

and second premolars. Depending on the location and quantity of MF, the effectiveness of a mental nerve block may be diminished<sup>53</sup>. In rare instances, the ineffectiveness of a mental nerve block may be due to the lack of MF. Radiographs and computed tomography may be used to identify MF with more accuracy and distinguish it from any radiolucent periapical lesions of lower premolars on radiographs taken routinely<sup>54</sup>.

Also, the literature indicates that preoperative clinical and radiological examinations of the MF are required for implantation surgery, particularly in the front mandible, to lower the possibility of interforaminal harm<sup>21,55</sup>.

Orthognathic surgeries have very significant operations performed as part of aesthetic surgery. Orthognathic operations involving the MF area include genioplasties and anterior segmental osteotomies<sup>56</sup>. The osteotomy cuts are designed based on the location of the MF as determined by radiography, the osteotomy cut may need modification into a step instead of being cut in a straight line. In certain circumstances, mental nerve transposition is also performed<sup>57</sup>.

### Conclusions

The mental foramen (MF) was located mostly apically to the second premolar, or between the two premolars. When comparing the average diameter of the MF between sexes, males came out on top. Compared to females, males had a more elongated anterior loop. In contrast to old X-ray modalities, CBCT has a higher rate of success in locating the anterior loop and accessory mental foramina.

### Conflict of Interest

The authors reported that they have no conflicts of interest.

### References

1. Singh R, Srivastav AK. Study of position, shape, size, and incidence of mental foramen and accessory mental foramen in Indian adult human skulls. *Int J Morphol*. 2010; 28(4):1141-46.
2. Alrahabi M, Zafar M. Anatomical variations of mental foramen: A retrospective cross-sectional study. *Int J of Morphol* 2018; 36(3):1-6.
3. Asrani VK, Shah JS. Mental foramen: A predictor of age and gender and guide for various procedures. *J Forensic Sci Med* 2018;4(2):76-84.
4. Arai Y, Tammsalo E, Iwai K, Hashimoto K, Shinoda K. Development of a compact computed tomographic apparatus for dental use. *Dentomaxillofac Radiol*. 1999;28(4):245-8.
5. Mozzo P, Procacci C, Tacconi A, Martini PT, Andreis IA. A new volumetric CT machine for dental imaging based on the cone-beam technique: preliminary results. *Eur Radiol*. 1998;8(9):1558-64.
6. Dawood A, Patel S, Brown J. Cone beam CT in dental practice. *Br Dent J*. 2009 11;207(1):23-8.
7. Sukovic P. Cone beam computed tomography in craniofacial imaging. *Orthod Craniofac Res*. 2003;6 Suppl 1:31-6; discussion 179-82.
8. Mah JK, Danforth RA, Bumann A, Hatcher D. Radiation absorbed in maxillofacial imaging with a new dental computed tomography device. *Oral Surg Oral Med Oral Pathol Oral Radiol Endod*. 2003;96(4):508-13.
9. Dos Santos Oliveira R, Rodrigues Coutinho M, Kühl Panzarella F. Morphometric Analysis of the Mental Foramen Using Cone-

- Beam Computed Tomography. *Int J Dent.* 2018;2018: 7. ID 4571895.
10. Aminoshariae A, Su A, Kulild JC. Determination of the location of the mental foramen: a critical review. *J. Endodontics* 2014;40(4): 471-75.
  11. Vujanovic-Eskenazi A, Valero-James JM, Sánchez-Garcés MA, Gay-Escoda C. A retrospective radiographic evaluation of the anterior loop of the mental nerve: comparison between panoramic radiography and cone beam computerized tomography. *Med Oral Patol Oral Cir Bucal.* 2015;20(2):e239-45.
  12. von Arx T, Friedli M, Sendi P, Lozanoff S, Bornstein MM. Location and dimensions of the mental foramen: a radiographic analysis by using cone-beam computed tomography. *J Endod.* 2013;39(12):1522-8.
  13. Ezoddini-Ardakani F, Safaee A, Safaei M, Sarikhani Khorrami KH. A review of anatomical variations of mental foramen (number, location, shape, symmetry, direction, and size). *J Shahid Sadoughi Univ Med Sci* 2016; 23(11): 1127-39.
  14. Khalid M, Manzoor F, Rashid A, Salman S, Khawaja SH Ahmed A. Radiological locations of mental foramen in the local population. *Ann Pak Inst Med Sci.* 2019; 15(3): 114-8.
  15. Greenstein G, Tarnow D. The mental foramen and nerve: clinical and anatomical factors related to dental implant placement: a literature review. *J Periodontol* 2006; 77: 1933-43.
  16. Apinhasmit W, Methathrathip D, Chompoonpong S, Sangvichien S. Mental foramen in Thais: an anatomical variation related to gender and side. *Surg Radiol Anat.* 2006; 28: 529–33.
  17. Bartling R, Freeman K, Kraut RA. The incidence of altered sensation of the mental nerve after mandibular implant placement. *J Oral Maxillofac Surg.* 1999; 57: 1408–12.
  18. Wismeijer D, van Waas MA, Vermeeren JI, Kalk W. Patients' perception of sensory disturbances of the mental nerve before and after implant surgery: A prospective study of 110 patients. *Br J Oral Maxillofac Surg.* 1997; 35: 254–259. PMID: 9291263
  19. Jacobs R, Lambrechts I, Liang X, Martens W, Mraiwa N, Adriaensens P, et al. Neurovascularization of the anterior jaw bones revisited using high-resolution magnetic resonance imaging. *Oral Surg Oral Med Oral Pathol Oral Radiol Endod.* 2007; 103: 683–93.
  20. Pommer B, Tepper G, Gahleitner A, Zechner W, Watzek G. New safety margins for chin bone harvesting based on the course of the mandibular incisive canal in CT. *Clin Oral Implants Res.* 2008; 19: 1312-16.
  21. Al Qahtani NA. Assessment of the position and level of mental nerve for placement of implants using cone-beam computed tomography & panoramic radiograph in the Saudi population. *Saudi Dent J.* 2022;34(4):315-20.
  22. Sheikhi M, Karbasi Kheir M, Hekmatian E. Cone-Beam Computed Tomography Evaluation of Mental Foramen Variations: A Preliminary Study. *Radiol Res Pract.* 2015;2015:1-5.ID 124635.
  23. Olasoji HO, Tahir A, Ekanem AU, Abubakar AA. Radiographic and anatomic locations of mental foramen in northern Nigerian adults. *Niger Postgrad. Med. J.* 2004;11(3): 230-3.
  24. Currie CC, Meechan JG, Whitworth JM, Carr A, Corbett IP. Determination of the mental foramen position in dental radiographs in 18–30 year olds. *Dentomaxillo. Radiol.* 2015;45(1):20150195.

25. Gungor K, Ozturk M, Semiz M, Brooks SL. A radiographic study of the location of mental foramen in a selected Turkish population on panoramic radiograph. *Coll Antropol.* 2006;30(4):801-5.
26. Verma P, Bansal N, Khosa R, Verma KG, Sachdev SK, Patwardhan N, Garg S. Correlation of Radiographic Mental Foramen Position and Occlusion in Three Different Indian Populations. *West Indian Med J.* 2015;64(3):269-74.
27. Jasim HH. Evaluation of Mental Foramen Location – A Review Article. *Journal of Medical Care Research and Review.* 2020;379-85.
28. Gada SK, Nagda SJ. Assessment of position and bilateral symmetry of occurrence of mental foramen in dentate Asian population. *J Clin Diagn Res.* 2014;8(2):203-5.
29. Kabak SL, Zhuravleva NV, Melnichenko YM, Savrasova NA. Topography of mental foramen in a selected Belarusian population according to cone beam computed tomography. *Imaging in Medicine* 2017;9(3):49-58.
30. Pelé A, Berry PA, Evanno C, Jordana F. Evaluation of Mental Foramen with Cone Beam Computed Tomography: A Systematic Review of Literature. *Radiol Res Pract.* 2021;2021:8897275.
31. Muínelo-Lorenzo J, Fernáández-Alonso A, Smyth-Chamosa E, Suaárez-Quintanilla JA, Varela- Mallou J, Suaárez-Cunqueiro MM. Predictive factors of the dimensions and location of mental foramen using cone beam computed tomography. *PLoS ONE* 2017;12(8): e0179704.
32. Goyushov S, Tözüm MD, Tözüm TF. Assessment of morphological and anatomical characteristics of mental foramen using cone beam computed tomography. *Surg Radiol Anat* 2018; 40, 1133-9.
33. Chen Z, Chen D, Tang L, Wang F. Relationship between the position of the mental foramen and the anterior loop of the inferior alveolar nerve as determined by cone beam computed tomography combined with mimics. *J Comput Assist Tomogr.* 2015;39(1):86-3.
34. Alsoleihat F, Al-Omari FA, Al-Sayyed AR, Al- Asmar AA, Khraisat A. The mental foramen: a cone beam CT study of the horizontal location, size, and sexual dimorphism amongst living Jordanians. *Homo* 2018; 69(6):335-9.
35. Chen JC, Lin LM, Geist JR, Chen JY, Chen CH, Chen YK. A retrospective comparison of the location and diameter of the inferior alveolar canal at the mental foramen and length of the anterior loop between American and Taiwanese cohorts using CBCT. *Surg Radiol Anat.* 2013;35(1):11-8.
36. Gungor E, Aglarci OS, Unal M, Dogan MS, Guven S. Evaluation of mental foramen location in the 10-70 years age range using cone-beam computed tomography. *Niger J Clin Pract.* 2017;20(1):88-92.
37. Naitoh M, Hiraiwa Y, Aimiya H, Gotoh K, Arijji E. Accessory mental foramen assessment using cone-beam computed tomography. *Oral Surg Oral Med Oral Pathol Oral Radiol Endod.* 2009;107(2):289-94.
38. Ritter L, Neugebauer J, Mischkowski RA, Dreiseidler T, Rothamel D, Richter U, Zinser MJ, Zoller JE. Evaluation of the course of the inferior alveolar nerve in the mental foramen by cone beam computed tomography. *Int J Oral Maxillofac Implants.* 2012;27(5):1014-21.
39. Gümüşok M, Akarslan ZZ, Başman A, Üçok Ö. Evaluation of accessory mental

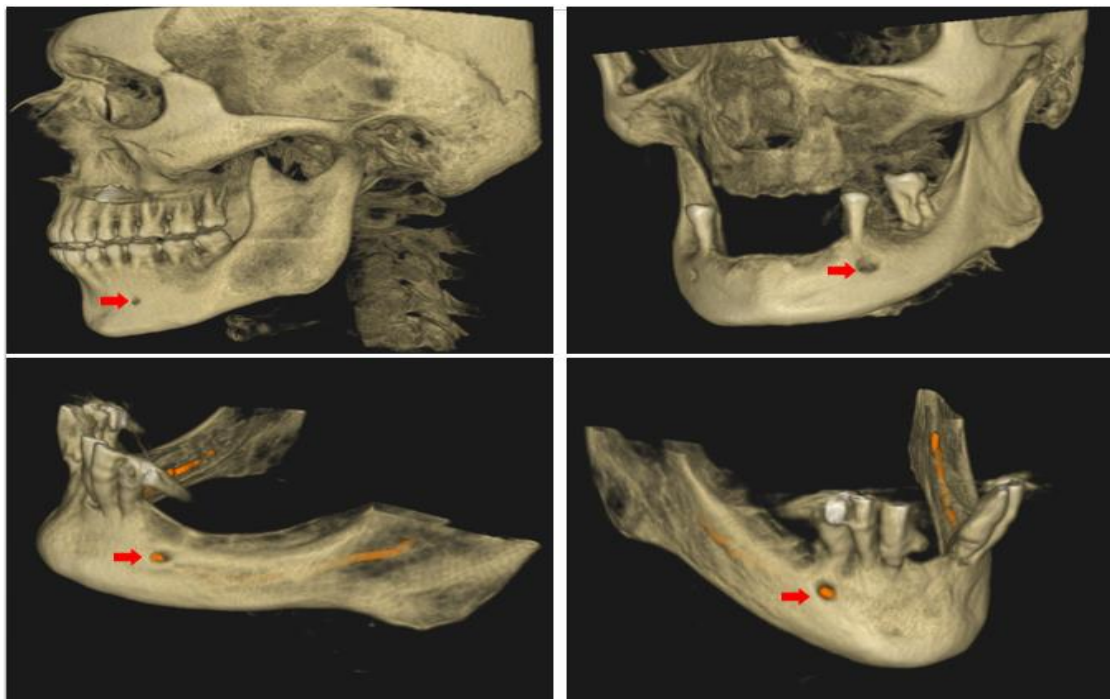
- foramina morphology with cone-beam computed tomography. *Niger J Clin Pract.* 2017;20(12):1550-4.
40. Bosykh YY, Turkina AY, Franco RPAV, Franco A, Makeeva MK. Cone beam computed tomography study on the relation between mental foramen and roots of mandibular teeth, presence of anterior loop, and satellite foramina. *Morphology.* 2019;103(341 Pt 2):65-71.
41. Sisman Y, Sahman H, Sekerci A, Tokmak TT, Aksu Y, Mavili E. Detection and characterization of the mandibular accessory buccal foramen using CT. *Dentomaxillofac Radiol.* 2012;41(7):558-63.
42. Katakami K, Mishima A, Shiozaki K, Shimoda S, Hamada Y, Kobayashi K. Characteristics of accessory mental foramina observed on limited cone-beam computed tomography images. *J Endod.* 2008;34(12):1441-5.
43. Carruth P, He J, Benson BW, Schneiderman ED. Analysis of the size and position of the mental foramen using the CS 9000 cone-beam computed tomographic unit. *J Endod.* 2015;41(7):1032-6.
44. Krishnan U, Monsour P, Thaha K, Lalloo R, Moule A. A limited field cone-beam computed tomography-based evaluation of the mental foramen, accessory mental foramina, anterior loop, lateral lingual foramen, and lateral lingual canal. *J Endod.* 2018;44(6):946-51.
45. Imada TS, Fernandes LM, Centurion BS, de Oliveira-Santos C, Honório HM, Rubira-Bullen IR. Accessory mental foramina: prevalence, position, and diameter assessed by cone-beam computed tomography and digital panoramic radiographs. *Clin Oral Implants Res.* 2014;25(2):e94-9.
46. M, Miloğlu Ö, Ersoy İ, Bayrakdar İŞ, Akgül HM. The assessment of accessory mental foramina using cone beam computed tomography. *Turkish Journal of Medical Sciences* 2013; (43):479-83.
47. Wang X, Chen K, Wang S, Tiwari SK, Ye L, Peng L. Relationship between the mental foramen, mandibular canal, and the surgical access line of the mandibular posterior teeth: A cone-beam computed tomographic analysis. *J Endod.* 2017;43(8):1262-66.
48. Eren H, Orhan K, Bagis N, Nalcaci R, Misirli M, Hincal E. Cone beam computed tomography evaluation of mandibular canal anterior loop morphology and volume in a group of Turkish patients. *Biotechnology & Biotechnological Equipment* 2016; 30(2):346-53.
49. Koivisto T, Chiona D, Milroy LL, McClanahan SB, Ahmad M, Bowles WR. Mandibular canal location: Cone-beam computed tomography examination. *J Endod.* 2016;42(7):1018-21.
50. Christopher P, Marimuthu T, Krithika C, Devadoss P, Kumar SM. Prevalence and measurement of anterior loop of the mandibular canal using CBCT: a cross-sectional study. *Clin Implant Dent Relat Res.* 2018;20(4):531-34
51. Wong SK, Patil PG. Measuring anterior loop length of the inferior alveolar nerve to estimate safe zone in implant planning: A CBCT study in a Malaysian population. *J Prosthet Dent.* 2018;120(2):210-13.
52. Sahman H, Sisman Y. Anterior loop of the inferior alveolar canal: A cone-beam computerized tomography study of 494 cases. *J Oral Implantol.* 2016;42(4):333-6.
53. Przystańska A, Bruska M. Accessory mandibular foramina: histological and immunohistochemical studies of their contents. *Arch Oral Biol.* 2010;55(1):77-80.

54. Ngeow WC, Yuzawati Y. The location of the mental foramen in a selected Malay population. *J Oral Sci.* 2003;45(3):171-5.

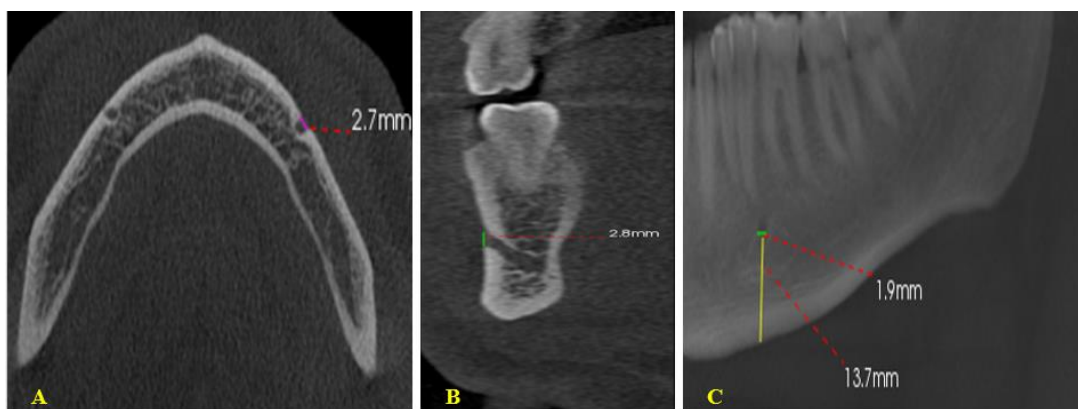55. Demir A, Izgi E, Pekiner F. Anterior loop of the mental foramen in a Turkish subpopulation with dentate patients: a cone beam computed tomography study. *MÜSBED* 2015; 5: 231-8.

56. Jääskeläinen SK, Peltola JK, Lehtinen R. The mental nerve blink reflex in the diagnosis of lesions of the inferior alveolar nerve following orthognathic surgery of the mandible. *Br J Oral Maxillofac Surg.* 1996;34(1):87-95.

57. Kahnberg KE, Ridell A. Transposition of the mental nerve in orthognathic surgery. *J Oral Maxillofac Surg.* 1987;45(4):315-8.



**Figure 1.** Cone beam CT image displaying the location of the mental foramen and shadow of the inferior alveolar nerve (red arrows).



**Figure 2.** A. The horizontal dimension (represented by the purple line) of the mental foramen in an axial plane, B. The cross-sectional image displays the vertical dimension of the mental foramen, as indicated by the green line; C. Width and distance of the mental foramen from the inferior border of the mandible display by sagittal plane.