




Cone Beam CT Description of Mental Foramen Variants: A Review

Nuhad A. Hassan ¹, Amal K. Jaloob ², and Abeer A. Aljoujou ³

¹ Department of Oral Medicine, College of Dentistry, Mustansiriyah University, Baghdad, Iraq

² Department of basic sciences, College of Dentistry, Mustansiriyah University, Baghdad, Iraq

³ Department of Oral Medicine, College of Dentistry, Damascus University, Damascus, Syria

Correspondence: Nuhad A. Hassan

Email: nihadalwan@uomustansiriyah.edu.iq

Received: 2 February 2023; Accepted: 10 September 2023; Published: 30 June 2024

Abstract

The mental foramen (MF) is a crucial marker for local anesthetic, surgical, and implantology treatments. After passing through the mandibular canal, the inferior alveolar nerve and blood vessels exit the MF as the mental vascular nerve. On radiographs, MF appears as a round or oval area of radiolucency inferiorly to the corpus mandible on the lateral sides (left and right). Consideration must be given to its morphology, location, and anatomical variances to minimize mental nerve harm. The focus of this literature review is to find out whether cone beam CT (CBCT) can accurately evaluate MF anatomy implantation and increase the clinician's understanding of this critical topic. Evidence-based research published between 1987 and 2022 was looked for in the literature using MEDLINE (PubMed), Web of Science, Scopus, the Iraq Virtual Science Library, and manual investigation of more sources. This was done to find articles that might be relevant. Between the two premolars, or apically to the second premolar, was where the MF was located most of the time. Men had larger mental foramens than women did, on average. Males tended to have a longer anterior loop than females. More frequently than panoramic, CBCT correctly identified the anterior loop and accessory MF.

Keywords: Mental Foramen, cone beam CT, anatomy, implant, morphology

Introduction

The mental foramen (MF) is placed on the lateral aspect of the mandible's body; it denotes where the inferior alveolar nerve and blood vessels exit the mandibular canal in the jaw. The mental bundle nourishes the lower lip, chin, and gingival tissue, with blood flow and sensory innervation (Singh R, Srivastav, 2010). The position and shape of the MF may vary according to variables such as age, gender, ethnic variations, and heredity (Alrahabi and Zafar, 2018; Asrani and Shah, 218). The MF is one of the most frequent locations of iatrogenic damage during anesthetic induction or surgery. Extraction of premolar and molar root tips, as well as implant placement in the mandibular

premolar area, are the most complex surgical procedures owing to the risk of neuro-sensory alterations in the lower lip and chin. If the MF is not adequately recognized and safeguarded, the danger of injury rises (Singh R, Srivastav, 2010).

Cone beam CT (CBCT) is a minimal-dose scanning approach developed for capturing images of the jaws and teeth with a revolving conical or pyramidal x-ray beam with a reciprocal image detector, CBCT can capture data from the whole volume of interest. This information is then utilized to create 2 or 3 dimensional (D) slices (Arai et al., 1999; Mozzo et al., 1998; Dawood A, Patel S, Brown, 2009; Sukovic, 2003; Mah et al., 2003; Dos Santos et al., 2018).



The CBCT provides non-superimposed 3D reconstructions of the oral cavity and distinct slices (axial, sagittal, and coronal) of the region of interest. Establishing quantitatively the MF's position and the existence of the anterior loop (AL) is currently best accomplished with high-resolution CBCT (Aminoshariae, Su and Kulild, 2014; Vujanovic-Eskenazi et al., 2015).

Prior to the advancement of dental rehabilitation procedures and the development of more precise 3D diagnostic images, researchers were also keenly interested in determining the anatomical variation of MF. However, this concern has gained a heightened level of significance due to the aforementioned developments in CBCT images (Von Arx et al., 2013; Ezoddini-Ardakani et al., 2016; Khalid et al., 2019).

Because of their clinical significance, the morphometric properties of MF are of particular interest. The MF can be damaged during surgical procedures, leading to paresthesia or numbness of the lower lip, and chin, and from the MF to the midline (Greenstein and Tarnow, 2006; Apinhasmit et al., 2006). Dental surgeons must precisely define the MF before performing bone augmentation, implant insertion, orthognathic surgery, and osteotomies during periapical surgery (Bartling, Freeman and Kraut, 1999; Wismeijer et al., 1997; Jacobs et al., 2007; Pommer et al., 2008). Therefore, the focus of this literature review is to find out whether CBCT can accurately evaluate mental foramen anatomy prior to implantation and increase the clinician's understanding of this critical topic.

Materials and Methods

Evidence-based research published between 1987 and 2022 was looked for in the literature using MEDLINE (PubMed), Web of Science, Scopus, the Iraq Virtual Science Library, and manual investigation of more sources. This was done to find articles that might be relevant. Review articles on similar topics that had been published before were also looked at to see if they might be relevant. For this, the words mental, cone beam CT, anatomy, implant, and morphology were used as keywords.

Only studies that were written in English and used CBCT images to characterize the MF's anatomical structure and the area around it were included. There were rules about what kinds of studies couldn't be used, such as panoramic studies, case reports, and research on children, and studies that used other kinds of CT. The comparison was based on sex, age, dentate state, and ethnic group.

Results

The first search yielded 60 papers. Eventually, 30 papers were included in the present review. For a better understanding, the key findings of the radiographic examination of the mental foramen characteristics are presented in the following topics:

In around 150 CBCT scans, Al-Qahtani highlighted that the most widespread form of MF was oval, then round (Al Qahtani, 2022). Similarly, Sheikhi et al. observed that oval pictures accounted for 69.4% of all scans in their research of 180 CBCT images, whereas round ones made up just 30% (Sheikhi et al., 2015). Ezoddini-Ardakani et al. mentioned that the most typical orientation of the MF is posterior-superior, and it can be oval or

circular in shape (Ezoddini-Ardakani et al., 2016).

Previous investigations often used panoramic images, which provide a flat view of a curved structure, suggesting that the imaging method may be to blame for the observed discrepancy. Radiology's CBCT yields a correct angular representation of curved structures, with the ability to reduce discrepancies.

In an investigation by Olasoji et al. (Olasoji et al., 2004), 34 percent of cases had the MF between the first and second premolars, and 24.5 percent had it under the second premolar's apex. Some research suggests that MF often occurs between the first and second premolars (Currie et al., 2015; Gungor et al., 2006; Verma et al., 2015; Jasim, 2020; Gada and Nagda, 2014).

CBCT images from 117 patients in Belarus were chosen at random. Most people's mental foramens were found in the space between their lower premolar roots (57.7%) or in the projection of their lower second premolar root (33.8%). Sixty-five percent of patients had an MF that extended below the tops of their roots. A projection line across the root apex was found to be the location of the foramen in 29.5% of the samples. The MF was found high up on the skull, above the root apex, in 5.6% of people. Most 84.2% of the MF was horizontally elongated ovals. The second most common variant (29.1%) has a canal that began mesially to the MF and then curved backward and upwards to create an anterior loop. So dental treatments in the anterior mandible are more successful and safer when the patient's own MF topography is updated using CBCT (Kabak et al., 2017).

The average diameter of the MF was observed to range from 2.08 ± 0.53 mm to 4.44 ± 1.13 mm by Pelé et al. (Pelé et al., 2021). Muinelo-Lorenzo et al., and Goyushov et al. both found that it was typically approximately 3 mm (Muinelo-Lorenzo et al., 2017; Goyushov, Tözüm and Tözüm, 2018). Males had a larger average diameter than females did across the literature; the gender gap might be as large as 0.62 mm (Dos Santos et al., 2018; Gada SK, Nagda, 2014; Chen et al., 2015; Alsoleihat et al., 2018; Chen et al., 2013; Gungor et al., 2017; Naitoh et al., 2009; Ritter et al., 2012; Gümüşok et al., 2017), Figures 1,2.

The accessory mental foramen (AMF)

According to research conducted by Bositykh et al. (Bositykh et al., 2019) and Sisman et al. (Sisman et al., 2012), the prevalence of AMFs varied from 2% to 26% among the groups investigated, with a higher incidence among males. The earlier authors typically found 1-2 AMFs per subject (Naitoh et al., 2009; Katakami et al., 2008; Carruth et al., 2015; Krishnan et al., 2018; Imada et al., 2014; Miloğlu et al., 2013). Fewer than 15% of people are thought to have an accessory MF, according to the majority of studies (Ezoddini-Ardakani et al., 2016). Ethnic variations have been shown to affect AMF incidence (Dawood, Patel and Brown, 2009; Sukovic, 2003; Dos Santos Oliveira et al., 2018; von Arx et al., 2013; Chen et al., 2015; Wang et al., 2017).

The anterior loop (AL) of the inferior alveolar nerve

The prevalence of AL varied from 10.4% to 94% between trials, and from 10% to 86% across sides studied (Eren et al., 2016; Koivisto et al., 2016; Christopher et al., 2018; Wong and Patil, 2018). Among many investigations, only two had a greater mean AL length in females (both 0.81 ± 1.18 and 6.5 ± 1.63 mm), suggesting that the AL mean

is longer in males (Chen et al., 2015; Sahman and Sisman, 2018).

Clinical importance of mental foramen anatomy

In local anesthetic administration for mental nerve block, the needle should be directed antero-inferior-medially and between the first and second premolars. Depending on the location and quantity of MF, the effectiveness of a mental nerve block may be diminished (Przystańska and Bruska, 2010). In rare instances, the ineffectiveness of a mental nerve block may be due to the lack of MF. Radiographs and computed tomography may be used to identify MF with more accuracy and distinguish it from any radiolucent periapical lesions of lower premolars on radiographs taken routinely (Ngeow and Yuzawati, 2003).

Also, the literature indicates that preoperative clinical and radiological examinations of the MF are required for implantation surgery, particularly in the front mandible, to lower the possibility of interforaminal harm (Al Qahtani, 2022; Demir, Izgi and Pekiner, 2015).

Orthognathic surgeries have very significant operations performed as part of aesthetic surgery. Orthognathic operations involving the MF area include genioplasties and anterior segmental osteotomies (Jääskeläinen, Peltola and Lehtinen, 1996) The osteotomy cuts are designed based on the location of the MF as determined by radiography, the osteotomy cut may need modification into a step instead of being cut in a straight line. In certain circumstances, mental nerve transposition is also performed (Kahnberg and Ridell, 1987).

Conclusions

The mental foramen (MF) was located mostly apically to the second premolar, or between the two premolars. When comparing the average diameter of the MF between sexes, males came out on top. Compared to females, males had a more elongated anterior loop. In contrast to old X-ray modalities, CBCT has a higher rate of success in locating the anterior loop and accessory mental foramina.

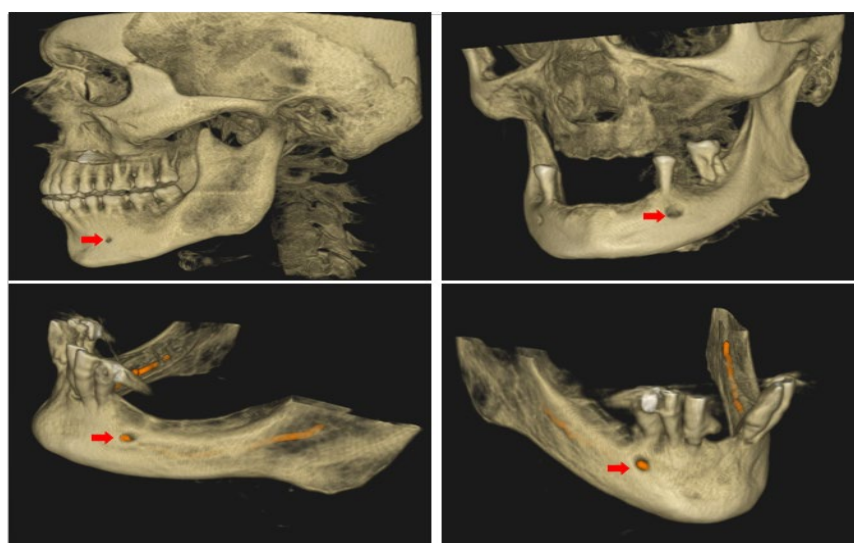


Figure 1: Cone beam CT image displaying the location of the mental foramen and shadow of the inferior alveolar nerve (red arrows).

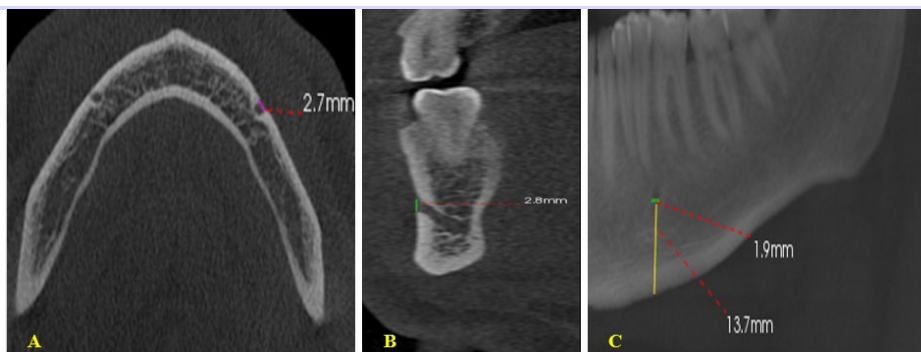


Figure 2: A. The horizontal dimension (represented by the purple line) of the mental foramen in an axial plane; B. The cross-sectional image displays the vertical dimension of the mental foramen, as indicated by the green line; C. Width and distance of the mental foramen from the inferior border of the mandible display by sagittal plane.

Supplementary Material

None.

Funding

This research received no external funding.

Data Availability Statement

Data are available from the authors upon reasonable request.

Conflict of interest

The authors reported that they have no conflicts of interest.

Acknowledgments

The authors would like to thank Mustansiriyah University (www.uomustansiriyah.edu.iq), Baghdad, Iraq, for their support in the present work.

References

1. Al Qahtani, N.A. (2022) 'Assessment of the position and level of mental nerve for placement of implants using cone-beam computed tomography & panoramic radiograph in the Saudi population', *Saudi Dental Journal*, 34(4), pp. 315-320. <https://doi.org/10.1016/j.sdentj.2022.04.001>
2. Alrahabi, M. and Zafar, M. (2018) 'Anatomical variations of mental foramen: A retrospective cross-sectional study', *International Journal of Morphology*, 36(3), pp. 1-6. <https://doi.org/10.4067/S0717-95022018000301124>
3. Alsolehhat, F., Al-Omari, F.A., Al-Sayyed, A.R., Al-Asmar, A.A. and Khraisat, A. (2018) 'The mental foramen: a cone beam CT study of the horizontal location, size, and sexual dimorphism amongst living Jordanians', *HOMO*, 69(6), pp. 335-339. <https://doi.org/10.1016/j.jchb.2018.11.003>
4. Aminoshariae, A., Su, A. and Kulild, J.C. (2014) 'Determination of the location of the mental foramen: a critical review', *Journal of Endodontics*, 40(4), pp. 471-475. <https://doi.org/10.1016/j.joen.2013.12.009>
5. Apinhasmit, W., Methathrathip, D., Chompoopong, S. and Sangvichien, S. (2006) 'Mental foramen in Thais: an anatomical variation related to gender and side', *Surgical and Radiologic Anatomy*, 28(6), pp. 529-533. <https://doi.org/10.1007/s00276-006-0119-7>
6. Arai, Y., Tammisalo, E., Iwai, K., Hashimoto, K. and Shinoda, K. (1999) 'Development of a compact computed tomographic apparatus for dental use', *Dentomaxillofacial Radiology*, 28(4), pp. 245-248. <https://doi.org/10.1038/sj.dmfr.4600448>
7. Asrani, V.K. and Shah, J.S. (2018) 'Mental foramen: A predictor of age and gender and guide for various procedures', *Journal of Forensic Science and Medicine*, 4(2), pp. 76-84. https://doi.org/10.4103/jfsm.jfsm_2_18
8. Bartling, R., Freeman, K. and Kraut, R.A. (1999) 'The incidence of altered sensation of the mental nerve after mandibular implant placement', *Journal of Oral and Maxillofacial Surgery*, 57(12), pp. 1408-1412. [https://doi.org/10.1016/S0278-2391\(99\)90720-6](https://doi.org/10.1016/S0278-2391(99)90720-6)
9. Bositykh, Y.Y., Turkina, A.Y., Franco, R.P.A.V., Franco, A. and Makeeva, M.K. (2019) 'Cone beam computed tomography study on the relation between mental foramen and roots of mandibular teeth, presence of anterior loop, and satellite

- foramina', *Morphologie*, 103(341 Pt 2), pp. 65-71. <https://doi.org/10.1016/j.morpho.2019.04.002>
10. Carruth, P., He, J., Benson, B.W. and Schneiderman, E.D. (2015) 'Analysis of the size and position of the mental foramen using the CS 9000 cone-beam computed tomographic unit', *Journal of Endodontics*, 41(7), pp. 1032-1036. <https://doi.org/10.1016/j.joen.2015.02.025>
11. Chen, J.C., Lin, L.M., Geist, J.R., Chen, J.Y., Chen, C.H. and Chen, Y.K. (2013) 'A retrospective comparison of the location and diameter of the inferior alveolar canal at the mental foramen and length of the anterior loop between American and Taiwanese cohorts using CBCT', *Surgical and Radiologic Anatomy*, 35(1), pp. 11-18. <https://doi.org/10.1007/s00276-012-0986-z>
12. Chen, Z., Chen, D., Tang, L. and Wang, F. (2015) 'Relationship between the position of the mental foramen and the anterior loop of the inferior alveolar nerve as determined by cone beam computed tomography combined with mimics', *Journal of Computer Assisted Tomography*, 39(1), pp. 86-93. <https://doi.org/10.1097/RCT.0000000000000166>
13. Christopher, P., Marimuthu, T., Krithika, C., Devadoss, P. and Kumar, S.M. (2018) 'Prevalence and measurement of anterior loop of the mandibular canal using CBCT: a cross-sectional study', *Clinical Implant Dentistry and Related Research*, 20(4), pp. 531-534. <https://doi.org/10.1111/cid.12609>
14. Currie, C.C., Meechan, J.G., Whitworth, J.M., Carr, A. and Corbett, I.P. (2016) 'Determination of the mental foramen position in dental radiographs in 18-30 year olds', *Dentomaxillofacial Radiology*, 45(1), pp. 20150195. <https://doi.org/10.1259/dmfr.20150195>
15. Dawood, A., Patel, S. and Brown, J. (2009) 'Cone beam CT in dental practice', *British Dental Journal*, 207(1), pp. 23-28. <https://doi.org/10.1038/sj.bdj.2009.560>
16. Demir, A., Izgi, E. and Pekiner, F. (2015) 'Anterior loop of the mental foramen in a Turkish subpopulation with dentate patients: a cone beam computed tomography study', *Marmara Üniversitesi Sağlık Bilimleri Enstitüsü Dergisi*, 5(3), pp. 231-238. <https://doi.org/10.5455/musbed.20150715121209>
17. Dos Santos Oliveira, R., Rodrigues Coutinho, M. and Kühl Panzarella, F. (2018) 'Morphometric Analysis of the Mental Foramen Using Cone-Beam Computed Tomography', *International Journal of Dentistry*, 2018, pp. 4571895. <https://doi.org/10.1155/2018/4571895>
18. Eren, H., Orhan, K., Bagis, N., Nalcaci, R., Misirli, M. and Hincal, E. (2016) 'Cone beam computed tomography evaluation of mandibular canal anterior loop morphology and volume in a group of Turkish patients', *Biotechnology & Biotechnological Equipment*, 30(2), pp. 346-353. <https://doi.org/10.1080/13102818.2015.1127181>
19. Ezoddini-Ardakani, F., Safaee, A., Safaei, M. and Sarikhani Khorrami, K.H. (2016) 'A review of anatomical variations of mental foramen (number, location, shape, symmetry, direction, and size)', *Journal of Shahid Sadoughi University of Medical Sciences*, 23(11), pp. 1127-1139.
20. Gada, S.K. and Nagda, S.J. (2014) 'Assessment of position and bilateral symmetry of occurrence of mental foramen in dentate Asian population', *Journal of Clinical and Diagnostic Research*, 8(2), pp. 203-205. <https://doi.org/10.7860/JCDR/2014/7257.4060>
21. Greenstein, G. and Tarnow, D. (2006) 'The mental foramen and nerve: clinical and anatomical factors related to dental implant placement: a literature review', *Journal of Periodontology*, 77(12), pp. 1933-1943. <https://doi.org/10.1902/jop.2006.060197>
22. Goyushov, S., Tözüm, M.D. and Tözüm, T.F. (2018) 'Assessment of morphological and anatomical characteristics of mental foramen using cone beam computed tomography', *Surgical and Radiologic Anatomy*, 40(10), pp. 1133-1139. <https://doi.org/10.1007/s00276-018-2043-z>
23. Gümüşok, M., Akarşlan, Z.Z., Başman, A. and Üçok, Ö. (2017) 'Evaluation of accessory mental foramina morphology with cone-beam computed tomography', *Nigerian Journal of Clinical Practice*, 20(12), pp. 1550-1554. <https://doi.org/10.4103/1119-3077.187329>
24. Gungor, E., Aglarci, O.S., Unal, M., Dogan, M.S. and Guven, S. (2017) 'Evaluation of mental foramen location in the 10-70 years age range using cone-beam computed tomography', *Nigerian Journal of Clinical Practice*, 20(1), pp. 88-92. <https://doi.org/10.4103/1119-3077.178915>
25. Gungor, K., Ozturk, M., Semiz, M. and Brooks, S.L. (2006) 'A radiographic study of the location of mental foramen in a selected Turkish population on panoramic radiograph', *Collegium Antropologicum*, 30(4), pp. 801-805.

26. Imada, T.S., Fernandes, L.M., Centurion, B.S., de Oliveira-Santos, C., Honório, H.M. and Rubira-Bullen, I.R. (2014) 'Accessory mental foramina: prevalence, position, and diameter assessed by cone-beam computed tomography and digital panoramic radiographs', *Clinical Oral Implants Research*, 25(2), pp. e94-e99. <https://doi.org/10.1111/clr.12066>
27. Jääskeläinen, S.K., Peltola, J.K. and Lehtinen, R. (1996) 'The mental nerve blink reflex in the diagnosis of lesions of the inferior alveolar nerve following orthognathic surgery of the mandible', *British Journal of Oral and Maxillofacial Surgery*, 34(1), pp. 87-95. [https://doi.org/10.1016/S0266-4356\(96\)90143-6](https://doi.org/10.1016/S0266-4356(96)90143-6)
28. Jacobs, R., Lambrechts, I., Liang, X., Martens, W., Mraiwa, N., Adriaensens, P. et al. (2007) 'Neurovascularization of the anterior jaw bones revisited using high-resolution magnetic resonance imaging', *Oral Surgery, Oral Medicine, Oral Pathology, Oral Radiology, and Endodontology*, 103(5), pp. 683-693. <https://doi.org/10.1016/j.tripleo.2006.11.014>
29. Jasim, H.H. (2020) 'Evaluation of Mental Foramen Location - A Review Article', *Journal of Medical Care Research and Review*, 3(7), pp. 379-385. <https://doi.org/10.15520/mcrr.v3i7.107>
30. Kabak, S.L., Zhuravleva, N.V., Melnichenko, Y.M. and Savrasova, N.A. (2017) 'Topography of mental foramen in a selected Belarusian population according to cone beam computed tomography', *Imaging in Medicine*, 9(3), pp. 49-58.
31. Kahnberg, K.E. and Ridell, A. (1987) 'Transposition of the mental nerve in orthognathic surgery', *Journal of Oral and Maxillofacial Surgery*, 45(4), pp. 315-318. [https://doi.org/10.1016/0278-2391\(87\)90351-X](https://doi.org/10.1016/0278-2391(87)90351-X)
32. Katakami, K., Mishima, A., Shiozaki, K., Shimoda, S., Hamada, Y. and Kobayashi, K. (2008) 'Characteristics of accessory mental foramina observed on limited cone-beam computed tomography images', *Journal of Endodontics*, 34(12), pp. 1441-1445. <https://doi.org/10.1016/j.joen.2008.08.033>
33. Khalid, M., Manzoor, F., Rashid, A., Salman, S., Khawaja, S.H. and Ahmed, A. (2019) 'Radiological locations of mental foramen in the local population', *Annals of Pakistan Institute of Medical Sciences*, 15(3), pp. 114-118.
34. Koivisto, T., Chiona, D., Milroy, L.L., McClanahan, S.B., Ahmad, M. and Bowles, W.R. (2016) 'Mandibular canal location: Cone-beam computed tomography examination', *Journal of Endodontics*, 42(7), pp. 1018-1021. <https://doi.org/10.1016/j.joen.2016.03.004>
35. Krishnan, U., Monsour, P., Thaha, K., Lalloo, R. and Moule, A. (2018) 'A limited field cone-beam computed tomography-based evaluation of the mental foramen, accessory mental foramina, anterior loop, lateral lingual foramen, and lateral lingual canal', *Journal of Endodontics*, 44(6), pp. 946-951. <https://doi.org/10.1016/j.joen.2018.01.013>
36. M, Miloğlu, Ö., Ersoy, İ., Bayrakdar, İ.Ş. and Akgül, H.M. (2013) 'The assessment of accessory mental foramina using cone beam computed tomography', *Turkish Journal of Medical Sciences*, 43(3), pp. 479-483. <https://doi.org/10.3906/sag-1205-87>
37. Mah, J.K., Danforth, R.A., Bumann, A. and Hatcher, D. (2003) 'Radiation absorbed in maxillofacial imaging with a new dental computed tomography device', *Oral Surgery, Oral Medicine, Oral Pathology, Oral Radiology, and Endodontology*, 96(4), pp. 508-513. [https://doi.org/10.1016/S1079-2104\(03\)00350-0](https://doi.org/10.1016/S1079-2104(03)00350-0)
38. Mozzo, P., Procacci, C., Tacconi, A., Martini, P.T. and Andreis, I.A. (1998) 'A new volumetric CT machine for dental imaging based on the cone-beam technique: preliminary results', *European Radiology*, 8(9), pp. 1558-1564. <https://doi.org/10.1007/s003300050586>
39. Muínelo-Lorenzo, J., Fernández-Alonso, A., Smyth-Chamosa, E., Suárez-Quintanilla, J.A., Varela-Mallou, J. and Suárez-Cunqueiro, M.M. (2017) 'Predictive factors of the dimensions and location of mental foramen using cone beam computed tomography', *PLoS ONE*, 12(8), e0179704. <https://doi.org/10.1371/journal.pone.0179704>
40. Naitoh, M., Hiraiwa, Y., Aimiya, H., Gotoh, K. and Ariji, E. (2009) 'Accessory mental foramen assessment using cone-beam computed tomography', *Oral Surgery, Oral Medicine, Oral Pathology, Oral Radiology, and Endodontology*, 107(2), pp. 289-294. <https://doi.org/10.1016/j.tripleo.2008.09.010>
41. Ngeow, W.C. and Yuzawati, Y. (2003) 'The location of the mental foramen in a selected Malay population', *Journal of Oral Science*, 45(3), pp. 171-175. <https://doi.org/10.2334/josnusd.45.171>
42. Olasoji, H.O., Tahir, A., Ekanem, A.U. and Abubakar, A.A. (2004) 'Radiographic and anatomic

- locations of mental foramen in northern Nigerian adults', *Nigerian Postgraduate Medical Journal*, 11(3), pp. 230-233. <https://doi.org/10.4103/1117-1936.175158>
43. Pelé, A., Berry, P.A., Evanno, C. and Jordana, F. (2021) 'Evaluation of Mental Foramen with Cone Beam Computed Tomography: A Systematic Review of Literature', *Radiology Research and Practice*, 2021, 8897275. <https://doi.org/10.1155/2021/8897275>
44. Pommer, B., Tepper, G., Gahleitner, A., Zechner, W. and Watzek, G. (2008) 'New safety margins for chin bone harvesting based on the course of the mandibular incisive canal in CT', *Clinical Oral Implants Research*, 19(12), pp. 1312-1316. <https://doi.org/10.1111/j.1600-0501.2008.01590.x>
45. Przystańska, A. and Bruska, M. (2010) 'Accessory mandibular foramina: histological and immunohistochemical studies of their contents', *Archives of Oral Biology*, 55(1), pp. 77-80. <https://doi.org/10.1016/j.archoralbio.2009.10.007>
46. Ritter, L., Neugebauer, J., Mischkowski, R.A., Dreiseidler, T., Rothamel, D., Richter, U., Zinser, M.J. and Zoller, J.E. (2012) 'Evaluation of the course of the inferior alveolar nerve in the mental foramen by cone beam computed tomography', *International Journal of Oral & Maxillofacial Implants*, 27(5), pp. 1014-1021.
47. Sahman, H. and Sisman, Y. (2016) 'Anterior loop of the inferior alveolar canal: A cone-beam computerized tomography study of 494 cases', *Journal of Oral Implantology*, 42(4), pp. 333-336. <https://doi.org/10.1563/aaid-joi-D-15-00038>
48. Sheikhi, M., Karbasi Kheir, M. and Hekmatian, E. (2015) 'Cone-Beam Computed Tomography Evaluation of Mental Foramen Variations: A Preliminary Study', *Radiology Research and Practice*, 2015, 124635. <https://doi.org/10.1155/2015/124635>
49. Singh, R. and Srivastav, A.K. (2010) 'Study of position, shape, size, and incidence of mental foramen and accessory mental foramen in Indian adult human skulls', *International Journal of Morphology*, 28(4), pp. 1141-1146. <https://doi.org/10.4067/S0717-95022010000400025>
50. Sisman, Y., Sahman, H., Sekerci, A., Tokmak, T.T., Aksu, Y. and Mavili, E. (2012) 'Detection and characterization of the mandibular accessory buccal foramen using CT', *Dentomaxillofacial Radiology*, 41(7), pp. 558-563. <https://doi.org/10.1259/dmfr/63250313>
51. Sukovic, P. (2003) 'Cone beam computed tomography in craniofacial imaging', *Orthodontics & Craniofacial Research*, 6(s1), pp. 31-36. <https://doi.org/10.1034/j.1600-0544.2003.259.x>
52. Verma, P., Bansal, N., Khosa, R., Verma, K.G., Sachdev, S.K., Patwardhan, N. and Garg, S. (2015) 'Correlation of Radiographic Mental Foramen Position and Occlusion in Three Different Indian Populations', *West Indian Medical Journal*, 64(3), pp. 269-274. <https://doi.org/10.7727/wimj.2014.143>
53. Von Arx, T., Friedli, M., Sendi, P., Lozanoff, S. and Bornstein, M.M. (2013) 'Location and dimensions of the mental foramen: a radiographic analysis by using cone-beam computed tomography', *Journal of Endodontics*, 39(12), pp. 1522-1528. <https://doi.org/10.1016/j.joen.2013.07.033>
54. Vujanovic-Eskenazi, A., Valero-James, J.M., Sánchez-Garcés, M.A. and Gay-Escoda, C. (2015) 'A retrospective radiographic evaluation of the anterior loop of the mental nerve: comparison between panoramic radiography and cone beam computerized tomography', *Medicina Oral, Patología Oral y Cirugía Bucal*, 20(2), pp. e239-e245. <https://doi.org/10.4317/medoral.20026>
55. Wang, X., Chen, K., Wang, S., Tiwari, S.K., Ye, L. and Peng, L. (2017) 'Relationship between the mental foramen, mandibular canal, and the surgical access line of the mandibular posterior teeth: A cone-beam computed tomographic analysis', *Journal of Endodontics*, 43(8), pp. 1262-1266. <https://doi.org/10.1016/j.joen.2017.03.043>
56. Wismeijer, D., van Waas, M.A., Vermeeren, J.I. and Kalk, W. (1997) 'Patients' perception of sensory disturbances of the mental nerve before and after implant surgery: A prospective study of 110 patients', *British Journal of Oral and Maxillofacial Surgery*, 35(4), pp. 254-259. [https://doi.org/10.1016/S0266-4356\(97\)90043-7](https://doi.org/10.1016/S0266-4356(97)90043-7)
57. Wong, S.K. and Patil, P.G. (2018) 'Measuring anterior loop length of the inferior alveolar nerve to estimate safe zone in implant planning: A CBCT study in a Malaysian population', *Journal of Prosthetic Dentistry*, 120(2), pp. 210-213. <https://doi.org/10.1016/j.prosdent.2017.10.019>