

Histological and Histomorphometric Evaluation of Socket Healing After Application of Epidermal Growth Factor with synthetic hydroxyapatite powder in Rats

Lobna K Al-khafaji ¹

¹ Osol Aldeen University College, Department of Dentistry, Iraq / Baghdad

Correspondence: Lobna K Al-khafaji

Email:

Received: 3 May 2023; Accepted: 20 June 2023; Published: 28 June 2023

Abstract

Aim of the study: One of the serious challenges in dental treatment is socket healing after tooth extraction. Various researchers have attempted to develop efficient therapies for healing and regenerating damaged tissues after extraction. Many tissue engineering technologies have been used now a day to enhance tissue healing. The present study was planned to evaluate the efficacy of epidermal growth factor with synthetic hydroxyapatite powder in socket healing.

Material and method: six-Thirty male rats were included in this study and their lower incisors teeth were subjected to extraction. Animals were divided into the following three groups according to socket treatment. (A) control, socket hole left to heal without any application, (B) application of hydroxyapatite powder (HAP) in the socket, (C) application of epidermal growth factor (EGF) with hydroxyapatite powder in the socket. Histological evaluation for bone formation, bone cell and inflammatory cell count with histomorphometry of bone trabeculae percentage had been done to all study groups and for three periods (5,14 &28 days).

Results: Epidermal growth factor with hydroxyapatite group showed early bone formation, more bone cell count, and less inflammatory cell infiltration in comparison to the HAP group and control at periods (5,14&28 days) and with a statistically significant difference ($p<0.05$). Bone trabeculae percentage was recorded to be high in the HAP&EGF group that filled the socket hole at (14 ,28 days) intervals in comparison to hydroxyapatite and control group. Complete re-epithelialization was observed only in the EGF&HAP group.

Conclusion: Both the HAP&EGF group and the hydroxyapatite group show bone formation and good socket healing, but the EGF&HAP group showed to be faster in filling of bony socket hole with complete epithelization than hydroxyapatite group, therefor using EGF with HAP is more efficient and suggested the material of choice used for socket healing.

Keywords: Bone healing, Bone cells, Hydroxyapatite, Epidermal growth factor, tooth socket.

Introduction

Socket healing is a complex biological process that shows specific regenerative and remodeling patterns and involves changes in many biological processes including the production and release of several important molecules^(1,2,3). Healing socket consists of three new tissue components; epithelium, connective tissue, and bone tissue. Interactive dynamic changes take place between these 3 components during healing period ⁽⁴⁾. The wound socket healing is influenced by various molecules, inflammation mediators,

integrin the growth factors that act on vascularization, new bone formation, and finally reepithelization covering socket surface⁽⁵⁾.

The process of socket healing requires involvement of cellular components including inflammatory cells, mesenchymal progenitor cells, endothelial cells, osteoblasts, osteocytes, and osteoclasts^(6,7,8). And sharing of inorganic materials that are important in the mineralization process of



bone, one of the most important materials is hydroxyapatite.

Hydroxyapatite is a type of mineral specifically, calcium apatite which presents naturally. It is comprised primarily of calcium and phosphate in a chemical formula $\text{Ca}_5(\text{PO}_4)_3(\text{OH})$ ⁽⁹⁾. It is found in crystalline-formed cells and has two separate structures. Hydroxyapatite interacts bio- specifically with proteins⁽¹⁰⁾. These interactions are the important in formation and strength of the bone. Many studies reported success of uses of HA in tissue- scaffolds in improving regeneration in orthopedic and craniofacial processes^(11,12).

Epidermal Growth Factor-EGF is a polypeptide of 53-amino acid isolated from the salivary glands of mice⁽¹³⁾. Epidermal Growth Factor has the ability to stimulate epithelial cells to grow and differentiate and reestablished the strength and the normality of injured tissues⁽¹⁴⁾. Epidermal Growth Factor can interact with many molecules and illustrates specific interaction with its receptor (EGFR) that lead to trigger a complex of biochemical processes and enhance the cell cycle to continue⁽¹⁵⁾. EGF is found to perform many functions concerned with the healing of oral mucosa, their functions include triggering cell proliferation, migration, and differentiation to specialized cells⁽¹⁶⁾. Many studies found that low EGF levels in wound area can be associated with inflammation that attacks the area and results in failure of healing^(17,18).

Many investigations in both human and animal models have been done on bone matrix and its mineralization to optimize socket healing^(19,20). In addition, HA can be used as a scaffold in bone tissue regeneration and with growth factors, it induces the release of inflammatory molecules and mediators⁽¹¹⁾. These researches provide direction for the present study to use biological materials for

the enhancement of socket healing and prevent its failure.

The study was designed to evaluate the efficacy of epidermal growth factor with synthetic hydroxyapatite powder in socket healing.

Materials and methods

A. Experimental animals

Thirty-six male Sprague-Dawley (SD) rats aged (3-3.5 months), weighing (200–250 g), were included in this study. All experiments were performed according to ethical approval from the ethical scientific committee of the Osol Aldeen University College and under the National Council's guide for the care of laboratory animals (Study No. 247-18/12/2022). The rats were kept in the Animal Department of Iraqi National Center of Drug Control and after 2 weeks of acclimatization, right and left lower incisors were extracted and grouped according to material that applicated in socket holes and to a subdivision according to post experimental periods as follows, Group control: right tooth socket hole left to heal spontaneously; Group HAP: left socket hole with HAP application; Group HAP&EGF: left socket hole with HAP&EGF application. Subdivision included periods (Days 5, 14, and 28) postoperatively.

B. Hydroxyapatite Micron Powder Purity: 99.5+%, Size: 3 μm , 5 grams / 0.1 g Nanografi / Germany.

C. Recombinant human EGF protein (Active) (ab285777), Lyophilized 10 μg (Abcam company)

Methods:

The rats were subjected to general anesthesia with a mixture of 50 mg/kg ketamine and 2.5 mg/kg xylazine. Lower incisors tooth extraction were done by application of labial and lingual movements using pedodontics forceps with minimal injury. After extraction, the socket irrigated with 0.09% saline and then drained with a sterile tampon. The left socket was treated with either 1 μg of HAP powder or 1 μg of lyophilized EGF with HAP (18 in number for each group), while the right socket concerned the control and left to heal spontaneously without any application (36 in number). The socket was closed using (3.0 silk) stitches thread. The animals were sacrificed by an overdose of carbon dioxide gas after surgical operation at the observation time (Days 5, 14, and 28) (6 rats for each period).

Specimens included socket with surrounding tissue were excised with a surgical saw and the excess tissue were dissected, then the specimens were removed with a 5–10 mm margin of surrounding bone. The specimens immediately were fixed into the 10%

formaldehyde solution, then the specimens were decalcified, dehydrated, embedded in wax and sliced in serial with 4- μm thickness, stained with H&E stain for histological and histomorphometric evaluation.

Histological and histomorphometric evaluation

The sections were studied under a light microscope and analyzed for bone cells and inflammatory cells that were counted at 5 representative fields with (X40) magnification ⁽²¹⁾. Patterns of cell organization, visualization, new bone formation and maturation, and epithelization of socket surface were observed for the control and experimental groups. The Trabecular areas were contoured and determined. The percentage of the Trabecular bone area of each group was gained by dividing the trabecular area / total area ⁽²²⁾ using the AxioVision,4.8 software (Carl Zeiss).

Statistical analysis: all data were entered into Excel spreadsheets for evaluation with the Statistical package deal for Social Studies (SPSS) (Chicago, IL, united states of America). The data were analyzed using ANOVA test.

Results

The current results illustrate the healing process on incisors rat's sockets at 5,14 and 28 days after

tooth extraction. All the histological analyses

of healing sequences followed on the socket's portions included cervical, middle and apical.

In general, all the study specimens showed the same histological features for healing but in different grades. As illustrated inflammation in early period, formation of granulation tissue & woven bone in mid period and bone formation and reepithelization in last period.

For the **Control group** the specimens at 5 days showed a blood clot in the cervical region of the socket. On the middle and apical

portions granulation tissue was observed with intense infiltration of inflammatory cells. A number of blood vessels also detected, figure (1A).

After 14 days of extraction, the socket showed woven bone formation on the middle and apical portions, while fibrous tissue was observed on cervical region with inflammatory cell infiltration, figure(1B). The last period 28 days of extraction illustrated thin bone trabeculae formation with no epithelization of the socket surface, figure(1C).

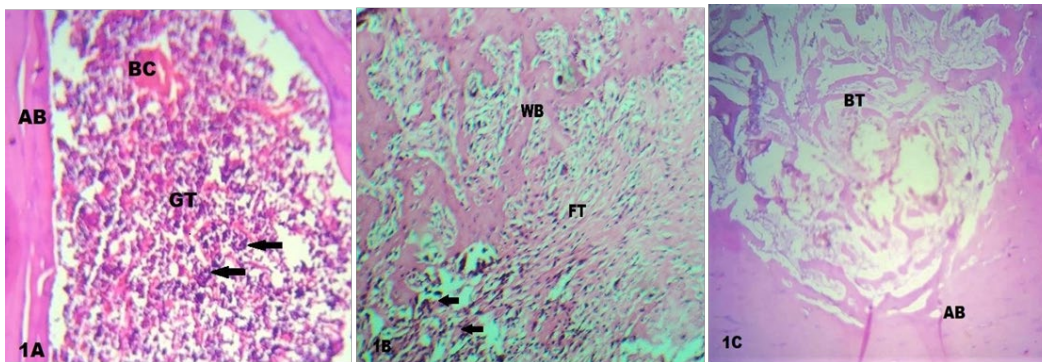


Figure 1: Microphotograph view for socket healing of control group at periods (days 5, 14&28). 1A: Socket at 5th day shows, Blood clot (BC), Granulation tissue (GT), Alveolar bone (AB), Inflammatory cells (arrows).H&E X20; 1B: Socket at 14th day shows, Woven bone (WB), Fibrous tissue (FT), Inflammatory cells (arrows).H&E X20; 1C: Socket at 28Th day shows, Bone trabeculae (BT), Alveolar bone (AB). H&E X10

For the **HAP group**, the specimens at 5 days showed a blood clot in the cervical region of the socket. On the middle and apical portions granulation tissue was observed with mild infiltration of inflammatory cell, figure (2A).

After 14 days of extraction, the socket showed bone trabeculae at apical portion,

figure(2B).

The last period 28 days of extraction illustrated bone formation on middle and apical portions with the presence of osteoblasts surrounding newly formed bone, and fibrous tissue on the mid half region of the middle portion with incomplete

epithelization of socket surface were detected too, figure(2C).

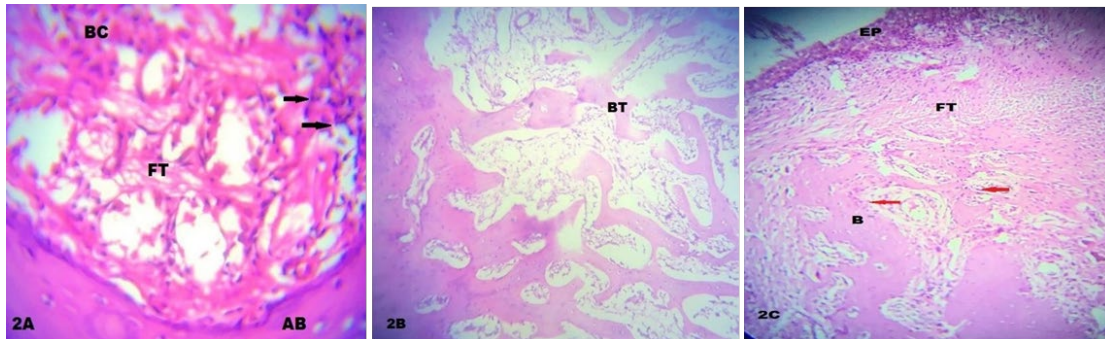


Figure 2. Microphotograph view for socket healing of HAP group at periods (days 5,14&28). 2A: Socket at 5th day shows, Blood clot (BC), Fibrous tissue (FT), Alveolar bone (AB), Inflammatory cells(arrows).H&E X20; 2B: Socket at 14th day shows, Bone trabeculae (BT). H&E X20 ;2C: Socket at 28th day shows, Bone (B), Fibrous tissue (FT), Epithelia (EP), Osteoblast (red arrows). H&E X10

For the **HAP&EGF group**, the specimens at 5 days illustrated early detection of a numerous number of osteoblast cells closely associated with woven bone on the apical portion. Fibrous tissue found in the middle area, figure (3A).

After 14 days of extraction, the socket recorded bone trabeculae filled apical and middle portions of the socket with enhanced osteoblasts surrounding the trabeculae,

osteocyte was also detected trapped in bone matrix. Fibrous tissue showed in the cervical region, figures (3B and 3C).

The last period 28 days of extraction revealed a progressive bone formation on the middle and the apical portions, fibrous tissue on mid half region of the middle portion followed by connective tissue with complete epithelization of the socket surface, figure(3D).

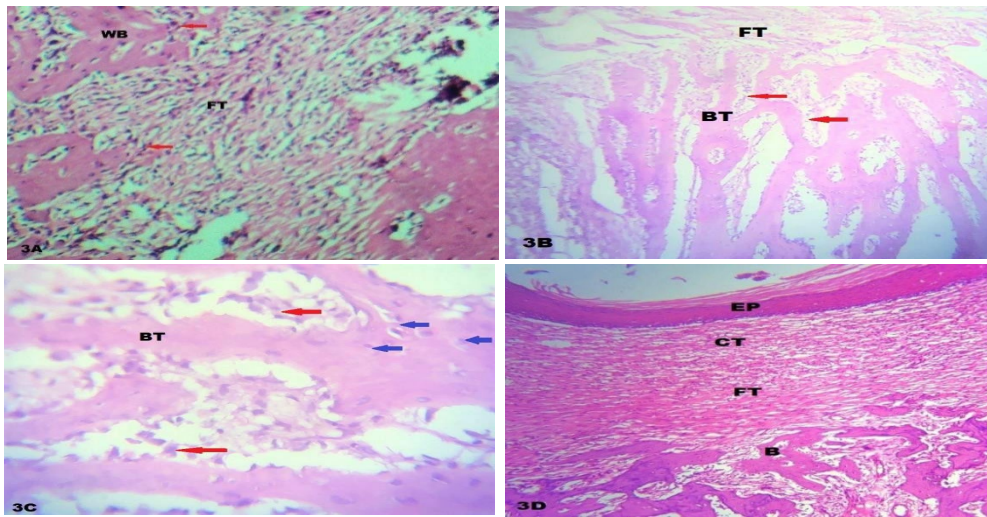


Figure 3. Microphotograph view for socket healing of HAP&EGF group at periods (days 5,14&28) 3A: Socket at 5th day shows, Fibrous tissue (FT), Woven bone (WB), Osteoblast (red arrows) .H&E X10. 3B: Socket at 14th day shows, Fibrous tissue (FT), Bone trabeculae (BT), Osteoblast (red arrows). H&E X10; 3C: Magnifying view for (3B view) shows, Bone trabeculae (BT), Osteoblast (red arrows), Osteocyte (blue arrows). H&E X20; 3D: Socket at 28th day shows, Epithelia (EP), Connective tissue (CT), Fibrous tissue (FT), Bone(B). H&E X10

Histomorphometric evaluation registered a statistically significant difference ($p < 0.05$) in the number of osteoblasts mean count at study periods (5,14&28 days) related to the HAP&EGF group in comparison to HAP & control groups, tables (1,2). While, inflammatory cell mean count revealed a

significant difference related to a control group in comparison to others, tables (3,4).

The percentage of bone trabeculae formation of study groups at 14&28 days was estimated and the result shows a significant difference ($p < 0.05$) related to the HAP&EGF group in comparison to HAP & control groups, figure (4) & tables (5,6).

Table 1: ANOVA test for Osteoblast mean count at ($2 \times 2 \text{mm}^2$) among study groups at periods (5,14&28 days)

Groups	5 days			14 days			28 days		
	Mean \pm SD	F value	P	Mean \pm SD value	F	P	Mean \pm SD value	F	P
Control	1.067 \pm 0.516	38.723	0.000	5.167 \pm 0.753	29.901	0.001	5.111 \pm 0.320	37.654	0.001
HAP	2.167 \pm 0.753			7.667 \pm 0.816			7.888 \pm 0.250		
HAP&EGF	4.333 \pm 0.516			9.500 \pm 0.548			8.500 \pm 0.330		

* Statistically significant at $p \leq 0.05$

Table 2: Post hoc test (LSD) of Osteoblast mean count among study groups at periods (5,14&28 days)

Groups	5 days		14 days		28 days	
	P-value	Sig	P-value	Sig	P-value	Sig
Control & HAP	0.046	S	0.034	S	0.031	S
Control & HAP&EGF	0.009	S	0.008	S	0.006	S
HAP& HAP&EGF	0.021	S	0.025	S	0.015	S

* Statistically significant at p<0.05

Table 3: ANOVA test for Inflammatory cell mean count at (2×2mm²) among study groups at periods (5,14&28 days)

Groups	5 days			14 days			28 days		
	Mean ±SD	F	P value	Mean ±SD value	F	P	Mean ±SD	F	P value
Control	20.037±0.316	12.130	0.000 *	16.160±0.453	10.136	0.001 *	4.022±0.420	16.133	0.001 *
HAP	9.133±0.443			6.667±0.416			2.888±0.320		
HAP&EGF	4.333±0.234			3.500±0.355			1.500±0.300		

* Statistically significant at p ≤ 0.05

Table 4: Post hoc test (LSD) of Inflammatory cell mean count among study groups at periods (5,14 &28 days)

Groups	5 days		14 days		28 days	
	P-value	Sig	P-value	Sig	P-value	Sig
Control & HAP	0.000	HS	0.000	HS	0.029	S
Control & HAP&EGF	0.000	HS	0.000	HS	0.000	HS
HAP& HAP&EGF	0.011	S	0.008	S	0.025	S

* Statistically significant at p<0.05

**P<0.001 High significant

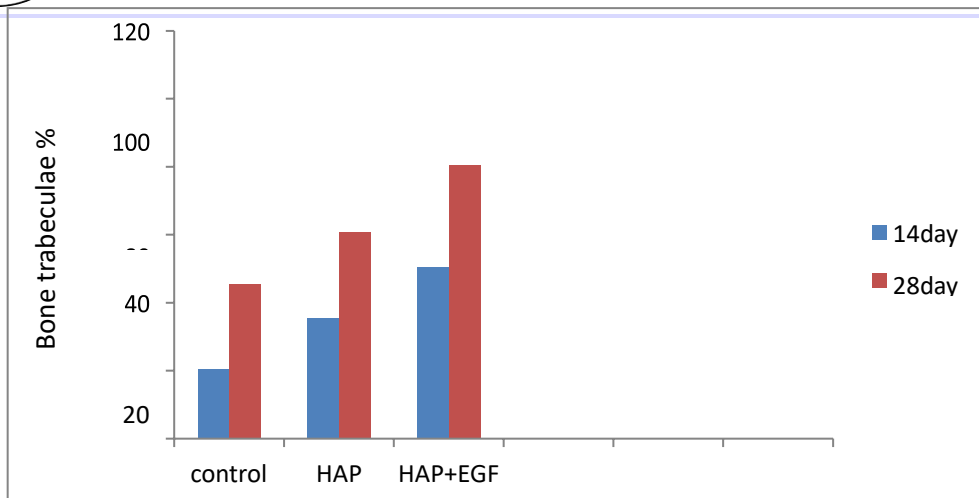


Figure 4: Bar chart for the percentage of bone trabeculae at 14&28 days

Table 5: ANOVA test for Percentage of bone trabeculae formation at (2×2mm²) among study groups at (14&28 days)

Groups	14 days			28 days		
	% of trabeculae	F	P value	% of value trabeculae	F	P
Control	20.600±6.22	27.430	0.001*	45.500±3.32	22.502	0.001*
HAP	35.500± 2.25			60.700±3.25		
HAP&EGF	50.600± 3.33			80.500±2.33		

* Statistically significant at $p \leq 0.05$

Table 6: Post hoc test (LSD) of Bone trabeculae formation among study groups at periods (14&28 days)

Groups	14 days		28 days	
	P-value	Sig	P-value	Sig
Control & HAP	0.045	S	0.017	S
Control & HAP&EGF	0.000	HS	0.000	HS
HAP& HAP&EGF	0.007	S	0.05	S

* Statistically significant at $p < 0.05$

** $P < 0.001$ High significant

Discussion

The present study was designed to find the efficacy of using a combination of EGF with hydroxyapatite in comparison to application of hydroxyapatite alone and control for evaluation of socket regeneration at periods (5,14&28 days). Bone cell count and inflammatory cell were recorded in the present study for the three periods as recognized easily, while estimation of bone trabeculae was done to periods (14&28 days) related to the time of its formation.

The current results for histological and histomorphometric evaluation of the HAP&EGF group show enhancement of proliferation of osteoblast, less inflammation and more percentage of bone trabeculae formation. These results may be attributed to the presence of an exogenous growth factor which is play an important role in bone restoration and increase response to the injured site that improves healing outcome⁽²³⁾. Also angiogenic effects of EGF acts a potent mitogen that triggered cell proliferation, migration and helps in the specialization of progenitor cells⁽²⁴⁾.

Present results reveal a low inflammatory cell infiltration in the socket of HAP&EGF group, these results coincide with Fonseca et al 2018⁽¹⁴⁾ who found that low EGF levels in

wound area can be associated with inflammation that attacks the area and resulted in failure of healing.

Recent results observe complete re-epithelialization after the healing of the socket in the HAP&EGF group more than in other groups, these results are in agreement with Kim et al. 2012⁽¹³⁾ who investigated that EGF is important molecules associated with epithelization of injured oral mucosa.

The Hydroxyapatite group presented woven bone at 5 days and bone trabeculae at 14 days and incomplete epithelization at 28 days. These results are in agreement with Samadian, et al. 2018⁽²⁵⁾ who showed a good result concerned to HA group which recorded a high rate of collagen synthesis with re-epithelialization and new blood vessel formation. Elsayed et al.2020⁽²⁶⁾ applied modified hydroxyapatite in wound healing and reported a high response in the proliferation and growth of cellular components of wound. Furthermore, Wardhana, et al. 2021⁽²⁷⁾ applied ellagic-hydroxyapatite to enhance bone healing by increasing the number of osteoblasts and secretion of osteoprotegerin and osteocalcin proteins. The current study suggests the use of EGF in the field of oral cavity regeneration and can be utilized clinically to

obtain good healing.

Conclusion: Epidermal growth factor application with HAP shows mitogen and osteoinductive proprieties that might be considered a hopeful biomaterial to be used in socket healing.

Ethical clearance: all work of this study had done according to the National Council's guide for the care of laboratory animals.

Conflicts of Interest

The authors declare that they have no conflicts of interest.

Funding

This research received no external funding.

Data Availability Statement

Data are available from the authors upon reasonable request.

Acknowledgments

The authors would like to thank to Dr. Ali Imad, Dr. Mohamed Abood and Dr. Ali Abbas.

References

1. Morgan EF, De Giacomo A, Gerstenfeld LC. Overview of skeletal repair (fracture healing and its assessment). *Methods Mol Biol.* 2014;1130:13-

31. https://doi.org/10.1007/978-1-62703-989-5_2
2. Einhorn TA, Gerstenfeld LC. Fracture healing: mechanisms and interventions. *Nat Rev Rheumatol.* 2015;11(1):45-54. <https://doi.org/10.1038/nrrheum.2014.164>
3. Ghiasi MS, Chen J, Vaziri A, Rodriguez EK, Nazarian A. Bone fracture healing in mechanobiological modeling: A review of principles and methods. *Bone Rep.* 2017;6:87-100. <https://doi.org/10.1016/j.bonr.2017.03.002>
4. Mokhtari S, Sanati I, Abdolahy S, Hosseini Z. Evaluation of the effect of honey on the healing of tooth extraction wounds in 4- to 9-year-old children. *Niger J Clin Pract.* 2019;22(10):1328-1334. https://doi.org/10.4103/njcp.njcp_102_19
5. Guo X, Hu H, Liu Y, Bao C, Wang L. The effect of haemostatic agents on early healing of the extraction socket. *J Clin Periodontol.* 2019;46(7):766-775. <https://doi.org/10.1111/jcpe.13122>
6. Al-Rashid M, Khan W, Vemulapalli K. Principles of fracture fixation in orthopaedic trauma surgery. *J Perioper Pract.* 2010;20(3):113-117. <https://doi.org/10.1177/175045891002000305>
7. Marsell R, Einhorn TA. The biology of fracture healing. *Injury.* 2011;42(6):551-

555. <https://doi.org/10.1016/j.injury.2011.03.031>
8. Berendsen AD, Olsen BR. Bone development. *Bone*. 2015;80:14-18. <https://doi.org/10.1016/j.bone.2015.04.035>
9. De Yoreo JJ. Research Methods in Biomineralization Science. *Sciencedirect*. 2013;532:2-614.
10. Ielo I, Calabrese G, De Luca G, Conoci S. Recent Advances in Hydroxyapatite-Based Biocomposites for Bone Tissue Regeneration in Orthopedics. *Int J Mol Sci*. 2022;23(17):9721. <https://doi.org/10.3390/ijms23179721>
11. Deng X, Gould M, Ali A. A review of current advancements for wound healing: Biomaterial applications and medical devices. *J Biomed Mater Res B Appl Biomater*. 2022;110(11):2542-2573. <https://doi.org/10.1002/jbm.b.35086>
12. Kwiatkowska A, Drabik M, Lipko A, Grzeczko A, Stachowiak R, et al. Composite Membrane Dressings System with Metallic Nanoparticles as an Antibacterial Factor in Wound Healing. *Membranes (Basel)*. 2022;12(2):215. <https://doi.org/10.3390/membranes12020215>
13. Kim KM, Lim J, Choi YA, Kim JY, Shin HI, Park EK. Gene expression profiling of oral epithelium during tooth development. *Arch Oral Biol*. 2012;57(8):1100-1107. <https://doi.org/10.1016/j.archoralbio.2012.02.019>
14. Fonseca MA, Costa LC, Pinheiro ADR, Aguiar TRDS, Quinelato V, Bonato LL, Almeida FLD, Granjeiro JM, Casado PL. Peri-implant mucosae inflammation during osseointegration is correlated with low levels of epidermal growth factor/epidermal growth factor receptor in the peri-implant mucosae. *Int J Growth Factors Stem Cells Dent*. 2018;1:17.
15. Schoichet JJ, Mourão CFAB, Fonseca EM, Ramirez C, Villas-Boas R. Epidermal Growth Factor Is Associated with Loss of Mucosae Sealing and Peri-Implant Mucositis: A Pilot Study. *Healthcare (Basel)*. 2021;9(10):1277. <https://doi.org/10.3390/healthcare9101277>
16. Teramatsu Y, Maeda H, Sugii H, Tomokiyo A, Hamano S. Expression and effects of epidermal growth factor on human periodontal ligament cells. *Cell Tissue Res*. 2014;357(3):633-643. <https://doi.org/10.1007/s00441-014-1877-x>
17. Yamawaki K, Matsuzaka K, Kokubu E, Inoue T. Effects of epidermal growth factor and/or nerve growth factor on Malassez's epithelial rest cells in vitro: expression of mRNA for osteopontin, bone morphogenetic protein 2 and vascular endothelial growth factor. *J Periodontal Res*. 2010;45(3):421-427. <https://doi.org/10.1111/j.1600-0765.2009.01254.x>

18. Furfaro F, Ang ES, Lareu RR, Murray K, Goonewardene M. A histological and micro-CT investigation in to the effect of NGF and EGF on the periodontal, alveolar bone, root and pulpal healing of replanted molars in a rat model - a pilot study. *Prog Orthod.* 2014;15(1):2. <https://doi.org/10.1186/2196-1042-15-2>
19. Burdusel AC, Gherasim O, Andronescu E, Grumezescu AM, Fica A. Inorganic Nanoparticles in Bone Healing Applications. *Pharmaceutics.* 2022;14(4):770. <https://doi.org/10.3390/pharmaceutics14040770>
20. Del Fabbro M, Tommasato G, Pesce P, Ravidà A, Khijmatgar S. Sealing materials for post-extraction site: a systematic review and network meta-analysis. *Clin Oral Investig.* 2022;26(2):1137-1154. <https://doi.org/10.1007/s00784-021-04262-3>
21. Accorinte ML, Holland R, Reis A, Bortoluzzi MC. Evaluation of Mineral Trioxide Aggregate and Calcium Hydroxide Cement as Pulp-capping Agents in Human Teeth. *J Endod.* 2008;34(1):1-6. <https://doi.org/10.1016/j.joen.2007.09.012>
22. Vilela RG, Gjerde K, Frigo L, Leal Junior EC, Lopes-Martins RA, Kleine BM, Prokopowitsch I. Histomorphometric analysis of inflammatory response and necrosis in re-implanted central incisor of rats treated with low-level laser therapy. *Lasers Med Sci.* 2012;27(3):551-557. <https://doi.org/10.1007/s10103-011-0937-7>
23. Min KK, Neupane S, Adhikari N, Sohn WJ, An SY. Effects of resveratrol on bone-healing capacity in the mouse tooth extraction socket. *J Periodontal Res.* 2020;55(2):247-257. <https://doi.org/10.1111/jre.12710>
24. Gomes MF, Abreu PP, Morosolli AR, Araújo MM, Goulart MD. Densitometric analysis of the autogenous demineralized dentin matrix on the dental socket wound healing process in humans. *Braz Oral Res.* 2006;20(4):324-330. <https://doi.org/10.1590/S1806-83242006000400008>
25. Samadian H, Salehi M, Farzamfar S, et al. In vitro and in vivo evaluation of electrospun cellulose acetate/gelatin/hydroxyapatite nanocomposite mats for wound dressing applications. *Artif Cells Nanomed Biotechnol.* 2018;46(sup1):964-974. <https://doi.org/10.1080/21691401.2018.1439842>
26. Elsayed MT, Hassan AA, Abdelaal SA, et al. Morphological, antibacterial, and cell attachment of cellulose acetate nanofibers containing modified hydroxyapatite for wound healing utilizations. *J Mater Res Technol.* 2020;9(6):13927-13936. <https://doi.org/10.1016/j.jmrt.2020.09.094>

27. Wardhana AS, Nirwana I, Budi HS, et al.
Role of Hydroxyapatite and Ellagic Acid
in the Osteogenesis. *Eur J Dent.*

2021;15(1):8-
12. <https://doi.org/10.1055/s-0040-1714039>