

Digital Techniques for Construction of Maxillofacial Prosthesis

Marwah Hussein Abdulsattar¹ and Sara Abdulbasit Turki¹

¹ Department of Prosthetic Dental Techniques, College of Health and Medical Techniques, Middle Technical University, Baghdad, Iraq

Correspondence: Marwah Hussein Abdulsattar

Email: marwah.hussein@mtu.edu.iq

Received: 23 April 2023; Accepted: 10 June 2023; Published: 28 June 2023

Abstract

Physiological flaws that impair appearances or functioning and prohibit a person from having a functional life often lead to the person seeking therapy that will restore an adequate standard of normality. The eye had been referred to several writers throughout history as the most priceless of endowments. It brings the whole outside world into our awareness that provides the deal with life, character, or respect. Consequently, the disappearance of an eye has traditionally been thought of as the ultimate sorrow as well as calls for prompt restoration so that the sufferer might resume living normally. Ocular prostheses use artificial material to simulate biological structure to provide the appearance of such a completely functional, regular eye as well as its surrounding structures. The precise replica of color, shape, or size is thus highly stressed in order to just provide people reality or harmony. The custom-made acrylics ophthalmic prosthetic or the implantation-maintained system are available as treatments. A bespoke ocular prosthetic is used because it offers the advantages of tight tissues interface adaptability with optimal convenience. This review outlines a more straightforward method for creating personalized ophthalmic prostheses.

Keywords: Ocular prosthetic, Polymethylmethacrylate, Eye prosthesis, CAD-CAM techniques.

Introduction

Information as well as telecommunications technologies evolved at an extraordinary pace inside this current millennium, so the year 2020 saw the synchronized development of numerous significant digital advancements

The major goal of this paper is to present a novel method of customization that uses the digitally snapshot of the individual's iris taken with a digital digicam to provide the individual with good aesthetic outcome.

Throughout time, ocular prostheses have changed, as different construction methods or material had been utilized. The methods covered in this review each have benefits or drawbacks. The Painting off approach improved patient acceptability or comfort. Whereas the image acquisition approach took fewer hours to deal with patients. These advancements may be equipped to solve a

number of the greatest pressing issues that health care organizations or policymakers are now grappling with, such as providing comprehensive, fair, yet affordable care to an expanding or increasing population^[1]

This article provides a summary of new technologies that might be used in tele-health and ophthalmologist. Lastly, this paper suggests whether, in light of a COVID-19 pandemic, ophthalmologist could adjust to the "new baseline" employing telemedicine or technological advances.

1. Eye prosthesis

The primary motivation for using an optical prosthesis is cosmetic. Our culture places a high priority on the visage with irises in particular. Prosthesis may assist preserve face proportion as well as significantly lessen



the visual impact of losing either or perhaps both functional eyeballs.

It may ease a broad range of social settings, particularly for kids. The damaged sight becomes obvious; even if there remains a lot can say regarding tolerating people with diverse physiques, particularly people who have had their bodies transformed by events beyond their influence. Synthetic glasses may reduce embarrassing queries or stares that could normally occur, whether as well as whether they are justified^[2]. Obtaining a synthetic eyeball to substitute a lost sight remains common practice, despite the fact that it isn't a strictly necessary diagnostic practice.

Nowadays, Plexiglas, a strong material, gets often used to create replacement eyes. Its artificial lens has a shell-like form.

An ophthalmic transplant is covered by the artificial eyeball. The corneal implantation is a distinct, angular, rigid object that gets persistently but physically implanted further in the lower eyelids^[3]. During implantation, an ophthalmic transplant has very often encased within live tissues or a manufactured softening substance. If you've been blinded because of an injury sustained or illness, a prosthesis eyelid might assist you look better. Popular ones for it include "glass eye" and "false eye." These components inside those lower eyelids are covered by a casing which is not actually a cornea. This artificial eyeball comes with:

- oblong, creamy outer layer completed to match another eyes and mouth white tint
- a center sphere with the retina as well as the cornea of a opposite eye drawn on it.
- It is nearly usually advised you transplant an artificial sight (visual prostheses) once an eyeball is medically eliminated because of an illness or injury. This implanted helps maintain healthy ocular functionality.

The following were a few causes for eyeball removal:

- eye cancers;
- glaucoma;
- eye infections;
- and injuries

Types of digital technique used for eye construction

With addition the creating alternative with traditional healthcare, newer innovations like genes, intelligent systems, and nanomaterials also have developed to continue providing new optometrists options for own medical practice. These were more evaluations inside the research concerning how novel surgeries, including as those for modeling before eye surgery as well as for corrective treatment, relate to advances^[4]. One of the numerous biodegradable and electrical technologies that possess the potential to offer an option for individuals with vision impairment is retinal implantation that includes semiconductors, cell lines, including novel components for ocular implanted. Powerful simulation tools have been developed across the visual world to instruct optometrists in these new recommendations.

1. The precision of internal fixation, creating of moulds and modeling, implanted retaining attachment, scaffolding, customized implantation, and temporary and ultimate prosthetics were all improved by desktop design a system, that rely on software packages. Simplify Circular Implants Placement throughout this Investigation The number of Twelve instances included the planning of insertion placement in orbital margins using EOIPlan but also Simplant Pro software.

2. Examine this area around the deformity as well as an ophthalmic socket. Just for undamaged eye, gauge the thickness of the cornea and the pupil, especially in the glare during the day. After that, inform the individual to focus on nothing in particular

while you take photos of the front of their faces, their orbits, including their natural eyes. Apply a thin layer of moisturizer on the faulty team's forehead or eyebrows. After cleaning the implant, compress the along using cloth granules or put cooled salt mixture into it^[5]. The main or diagnosis visual perception may thus be made swiftly.

3. To softened modeling beeswax (DPI), add waxed in a silicone dish using heated air. Then, adjust it to the front of its facial having both a flaw suitably positioned surrounding it.

4. Biopolymer were used to create the diagnostics impressions, then sterilized injections without needles were used to shoot the betonies into the sockets as well as keep the seaweed in place while pouring the gelato from outside eye socket utilizing bits of paper inserted in the gelato.

5. As soon as the imprint is created, stabilize this with support composed from cement of Parisian type-II (ultra dent). The assumption then had been carefully removed. and packaged with sculpting sealan prior to actually even being pumped in two steps have used type-IV dentists rocks (ultra dent) and prepared correctly four searchable buttons on the first spilling^[6]. Trying to separate moderate cooler mold cavity wrap (DPI) was after which decided to apply just before second spilling with type-IV dentists rock designated superiors, inferiority, median, proximal, and completely undermines being covered using beeswax even as casting were made then appropriately shaped, as well as a specific plate were made with self-curing mono meth acrylic acid (DPI)

6. A tunnel created in this same special plate must have been encrusted to box sealant, with infusion and vinyl polymerized illumination body (coltene /wahldent, Germany), with very little infusion inside this same intravenous Fig. 1(L), as well as concurrently actively supporting with biopolymer (DPI), to repetition of a safety pins, or continuing to

assistance it with quickly gypsum of France type-II dentist's rock.

7. Its special plate has been assessed for just some aggressive expansion inside the ophthalmologic defect and rectified prior to actually post production (ultra dent).

8. The casting was created as before, with the same markings for mesiodistal, proximal, superiors, and inferior. The readymade eye covering was used to complement the participant's digital images, which were obtained from various perspectives.

2. CAD-CAM techniques

One goal of research analysis of the literature was to compile the technological and therapeutic uses of CAD/CAM technologies for the pre - surgical of a location of maxillofacial implantation, development of moulds and structural components, and manufacture of ophthalmic prosthesis. The computerized analysis was conducted in accordance with the preferred Reporting Items for Systematic Reviews and Meta-Analysis (PRISMA) standards. Computerized planned task for the implant placement of ophthalmic abnormalities in clinical investigations included incorporated. For Fifteen instances, Ct scanners, five cases used the 3DSS-STD-II biometric scanner, Three instances was using an Artec Color 3D scanner, or two cases used a Next Engine Desktop 3D imaging system were the most frequent preliminary information needed for computerized modeling. Easy Orbital Implant Planning EOIPlan program was used in eight instances, Geomagic program in eight, Simplant technology in 4 trials, and Artec Studio 12 Professional in three cases as electronic software system^[6]. For 12 patients, surgery patterns being created so order to insert 41 mandibular implants in the region of the ocular deformity. 5 ocular transplants were inserted using a graphics surgical navigation system for two patients. For the treatment planning of maxillofacial implants,

development of mounds and structural components, and manufacturing of ophthalmic prosthesis, computerized engineering and printed methods have been documented. The studies have found that virtual strategic plan, constructing, and falsification of planetary prosthetic limbs cut down on general practice and research lab wait times, decreased patients, as well as produced satisfying performance; nevertheless, the utilization of such computer data has been constrained by a lack of technical experience and high equipment.

That research introduces an ocular prosthetic renewed that is desktop. By using the child's native eyeball as a reference, the method makes it simple to recreate a 3d representation of the ophthalmic prosthetic from such a Computed tomography, allowing users to preview the outcome of rehabilitative procedures ahead of time. This makes it easier for physicians to create suitable orbital prostheses and enhance the aesthetics of therapy. The technique could potentially be used to arrange the preparatory operation for an ocular implantation. This greatly enhances the rehabilitative treatments dependability, comfort, and intelligence^[7]. Diagnostic Tomography pictures from individuals have been utilized to test the system, and the outcomes of the study demonstrate its efficacy as well as acceptance in the hospital. Complicated prostheses such circular prostheses may now be manufactured more easily as well as quickly because to advances in mobile technology such rapid prototyping and CAD/CAM. Most modern methods need specific expertise, special equipment, and could not be readily accessible. Accordingly, craniofacial conditions are considered should indeed to be competent in understand the existing morphological guidelines then utilize them to build a visually appealing prostheses utilising validated tools to quickly improves long' living comfort and aid in their rehabilitation.

Genetic and inherited abnormalities may cause ocular deformities. Tumors or trauma may cause inherited problems in the ocular region, whereas developing abnormalities could cause hereditary deformities. Among the more invasive robotic surgery, exenteration of the eyeball has often used following ocular tumor removal^[8]. The prosthetics choices that enhance for clients' aesthetics as well as living satisfaction play a major role with in rehabilitation of an exenteration problem. The mechanical treatment of exenteration frontal abnormalities was much less difficult with both the development of Osseo integrated implantation because they increase the preservation, supporting, and durability of temporal prosthesis.

The longevity and effectiveness of fitted, nevertheless, might suffer from incorrect design and location of these devices. Surveys had shown success around 35-75% after 3–14 decades of monitoring. The geographic placement, amount as well as condition of marrow, general wellness, and radiotherapy treatment dosage all affect achievement. The ocular country's inadequate bones supply, which is primarily relatively thin containing minimal to zero blood, makes it difficult for cranial prosthesis to Osseo integrate there^[9]. As a result, overall importance for clinical evaluation with perioperative procedural guidance has increased again for successful application of ocular implantation and frontal augmentation prosthetics.

Inside these realms of surgery including prosthetics, computerized tools have revolutionized the industry. During greater over fifteen years, implantation insertion has been performed using desktop development and desktop fabrication techniques (CAD/CAM). Personalized medical implantation guidelines may well be created using this 3d modeling, allowing the preliminary planned information to be transmitted for use during surgery in exact

internal fixation. Typically, non - contact three-dimensional imaging modalities including computed tomography (CT), cone beam-computed tomography (CBCT), as well as magnetic resonance imaging (MRI) are used for gather the preliminary data for computerized design, as well as a variety of lidar systems^[10].

Especially contrasted to traditional operational guidance, Sarment et al. claim that using CAD/CAM operative templating greatly improves the reliability or efficiency of placing new teeth. Additionally, recent cranial implantation surgeries have included CAD/CAM technologies without better clinical results. During cranial operations relatively lately, navigational devices were utilized. Those technologies provide physicians the ability to manipulate the placement as well as movements of tools using computed tomographic images of clinical imagery. When in touch with a client, a navigational marker other specially designed device identifies that precise place inside a radiography picture, enabling surgery practitioner can concurrently traverse within in the operative area and simulated anatomy mapping^[11]. Stationary but also adaptive navigational were employed as proper installation methods since the advent of navigational aids in the area of dental implantology.

In contrast to dynamic guidance, typically rising action operative models all through bone cutting and internal fixation, dynamically transportation uses 3D technology to provide real-time surveillance of bones excavation as well as eventual implant - supported all across the process. Based on its proponents, CAD/CAM technologies may shorten clinical and lab process durations and reduce customer visits while maintaining the therapeutic result. Again for joint replacement for ocular abnormalities, CAD/CAM technologies has being utilized to fabricate operative patterns,

prototypes, moulds, structural components, bespoke implanted, and assisted implantation procedures^[12-13]. That original study objective is to collect patient records to solve the relevant query: Which are the technological and therapeutic uses of CAD/CAM technologies for the implant placement, designing, and production of ophthalmic prosthesis in individuals with ophthalmic imperfections?

As quickly as you have healed from of the eyeball depending on the chemical operation, it really is crucial to use prosthesis to repair the visual deformities. Stock prosthesis in a range of sizes, dimensions, as well as colors may fill the demand for a synthetic sight. Old methods for creating personalized ophthalmic prosthesis (COPs) are a lengthy process since they include a number of intricate processes that heavily rely on the oculist's knowledge. Regarding real practice, there remains a poor fit among COPs and patients' scleral sacs that might also result in discomfort, leakage, as well as a diminished look. In order to suit various anophthalmia sockets or construct COPs without greater precision, there has important to establish a novel process^[14].

The conventional process for creating COPs is as described in the following:

- 1) Modelling the cornea sack in beeswax when it melted after boiling;
- 2) Creating a plasterboard mould based on a hydrocarbon image;
- 3) For create the impenetrable plastic design, combine the epoxy only with oxygenation antifungal medication powdered but also resins solution inside its appropriate amounts, then then drop something that through into plasterboard framework;
- 4) Shading: utilizing an oily pigments, paintbrush, adhesive, and SAP to manually color based on the standards of a normal vision;
- 5) Apply transparent SAP and over colorful, impenetrable epoxy substrate.

6) Putting it all on, monitor your progress for three or six months, but also adjust these multiple occasions to fit the sclera sack before the eye socket was fully structured. Scleral sack modelling was a crucial component of that process, although how well it works depends frequently on eye individual medical expertise of the treating physician including the level of customer participation.

Additionally, the procedure through the gel membranes to the beeswax mould that is appropriate for the child's lachrymal sac region was challenging, moment, as well as highly susceptible to doctor-interference. Alongside the advancement of Renewable, a digitalized image was created using reconstructions using an extant actual item. Reverse engineering (RE) software solutions could swiftly sort surfaces point cloud information and dynamically produce matrices, enabling might produce arbitrarily complicated extremely precise representations and produce elevated 3D theories^[15]. These capabilities were founded on sophisticated computer simulations including interface building theories. Studies in medicine have made extensive usage RE technology because to their benefits in surfaces matching. Consequently, including Renewable innovations into the manufacturing for COPs may enhance architectural accuracy but also visualization. The technique of 3d printers is ideal for correctly producing an item from a template. The basic technique utilized in fused deposition (FDM) technologies was indeed one thermal freezing and adherence of thermoses, which were built one level at a time beneath electronic controls to produce the treated organism. A computer-controlled FDM warming heads heats the substance (such as ABS, polyamide, beeswax, as well as various substances) to a middle of the action while simultaneously moving the nozzles components through the bridge

contouring or refilling route. Accelerated chemical solidification as well as texture adhesion led to the formation of 3D object from its bottom up. A goal for that project was to create a laptop moderately process in developing and producing COPs that might improve the COP's form and make it much better pleasant to wearing^[16]. Reverse engineering (RE), three-dimensional (3D) manufacturing, as well as similar methods used in desktop manufacturing as well as layout (CAD/CAM) could deliver fresh concepts for creating or constructing COPs. Its creation for such 3D image was challenging since the physiology of the eyeball was intricate as well as complicated. Additionally, a wide variety of fabrication techniques must be paired alongside the choice of scanning process.

With the employment or fused deposition modeling (FDM) or stereo lithography (SLA) enabled technologies, computer-aided

manufacturing (CAM) transforms conceptual thinking and creating into actuality by producing models, shellac, moulds, operative templating, or straight prosthetics. A polymer thread gets melted then produced using an extruder head here on depositing substrate inside the FDM process. The regulated warm airflow causes this extrusion polymer it become rigid as quickly as it was placed^[17]. By that manner, each implanted upon this a simulation in sheets over time. Method protrusion components is necessary to construct more intricate testable theories technique makes use of materials like polycarbonates, polyamide butyro styrene (ABS), or polysulfones, whereas photolithography cures photographic glue with Ultraviolet rays. It's incredibly violet cure, which was applied after each phase of depositing, eventually creates the necessary structured form via polymerization and subsequent coatings. The monomers material

used in Provider manufacturing technologies is photopolymerized to create a polymeric^[18]. Although SLA printing were utilized to create operational prototypes for made completely procedures, FDM printing are mostly utilized to create models for clinical evaluation, moulds, temporary bridges and crowns shellac, including personalised biting registers. Every approach offers benefits or drawbacks of their nature. Eight examples in the current research included the usage of Printers. Throughout these 7 instances, acrylonitrile butyry styrene (ABS) remained the substance chosen when manufacturing moulds for laparoscopic patterns, whereas polyester polymer was chosen printed substance on selection for those 10 examples which utilized Scalability machines.

3. 3D printer techniques

When an object gets printed using three dimensions (3D), it is constructed level by level from a computer-aided design (CAD) sketch. That technology makes it easier to create unique things having intricate shapes but also to use improvisation designs. Additionally, that kind of manufacturing gets employed in the healthcare industry, in which it is starting to transform diagnostic but also therapeutic operations. But even while ophthalmic prosthesis has lately been made via 3D printing^{11,12}, there is still potential for improvement^[19]. The production of specialized ocular prosthesis utilizing 3D printers and interface spraying methods is proposed as a tractor trailer procedure in that research. The suggested method may produce patient-specific ocular prosthesis without a heavy dependence on knowledgeable oculists^[20]. This specially constructed polymers implant known as an optical prosthesis may be used to restore the appearance of people that having destroyed both eyeballs.

One such handmade ophthalmic prostheses requires physical creative effort, which adds

to the labor cost required for the operation. The three-dimensional (3D) printer combined sublimated photolithographic techniques are combined in this research to present a new semi-automated approach to constructing unique ophthalmic prosthesis. The suggested approach begins by mechanically scanning the participant's an ophthalmic hole imprint mold that use a 3D scanner to create a 3D image. The optical prosthetic was subsequently created utilizing biodegradable photo curable polymer and a based on a digital treatment printer. The corresponding natural eye's picture was modified to create a representation of the cornea and vasculature, which is then transferred utilizing just the textile printing required to separate onto the 3D-printed ophthalmic prosthetic^[21]. These are minimal negative effects in biological survival or reproduction, according to cytotoxicity evaluations of the basic substance as well as manufactured ophthalmic prosthetic. The suggested approach should make it simpler for sufferers to get high-quality, handmade ophthalmic prosthetic since it takes less effort as well as effort to build them.

4. 3D printer techniques

When an object gets printed using three dimensions (3D), it is constructed level by level from a computer-aided design (CAD) sketch. That technology makes it easier to create unique things having intricate shapes but also to use improvisation designs. Additionally, that kind of manufacturing gets employed in the healthcare industry, in which it is starting to transform diagnostic but also therapeutic operations. But even while ophthalmic prosthesis has lately been made via 3D printing^{11,12}, there is still potential for improvement^[19]. The production of specialized ocular prosthesis utilizing 3D printers and interface spraying methods is proposed as a tractor trailer procedure in that research. The suggested method may produce

patient-specific ocular prosthesis without a heavy dependence on knowledgeable oculists^[20]. This specially constructed polymers implant known as an optical prosthesis may be used to restore the appearance of people that having destroyed both eyeballs.

One such handmade ophthalmic prostheses requires physical creative effort, which adds to the labor cost required for the operation. The three-dimensional (3D) printer combined sublimated photolithographic techniques are combined in this research to present a new semi-automated approach to constructing unique ophthalmic prosthesis. The suggested approach begins by mechanically scanning the participant's an ophthalmic hole imprint mold that use a 3D scanner to create a 3D image. The optical prosthetic was subsequently created utilizing biodegradable photo curable polymer and a based on a digital treatment printer. The corresponding natural eye's picture was modified to create a representation of the cornea and vasculature, which is then transferred utilizing just the textile printing required to separate onto the 3D-printed ophthalmic prosthetic^[21]. These are minimal negative effects in biological survival or reproduction, according to cytotoxicity evaluations of the basic substance as well as manufactured ophthalmic prosthetic. The suggested approach should make it simpler for sufferers to get high-quality, handmade ophthalmic prosthetic since it takes less effort as well as effort to build them.

3.1 3D modeling of ocular prosthesis impression model

Figure. 1, displays the key processes in either the traditional technique as well as the moderately approach that is suggested for developing personalized ophthalmic prosthesis. An imprint of the targeted participant's an ophthalmic sockets was initially required for the creation of a personalized corneal prostheses. As a result, its prosthetic' dimensions as well as form were

determined by injecting a sufficient quantity of adhesive layer into the participant's an ophthalmic sockets^[22]. The prospective pupil center of the optical prosthetic was traced on such an impressions mould and compared to the opposite unaffected companion eyeball. Another of the writers (S.W.B), an expert ocularist, carried out that.

Monitoring equipment is needed to gather details regarding with given organism's dimensions as well as establish as well as to generate information into 3D models. The information from 3D models that may be created using magnetic resonance (MR) and computed tomography (CT) images, could indeed be obtained using a variety of non-contact approaches^[23]. To guarantee that now the data may be utilized for 3D modeling, nevertheless, additional equipment being needed since CT as well as MR scans were meant to therapeutic usage. Additionally, respective sensitivities were constrained. As an approach, it is possible the employ the strength of the lighting (visual image) approach, where involves shining a flashlight on a substrate with the goal to immediately get three - dimensional modeling data. In our investigation, we employed a luminosity 3D scanning to acquire 3D modeling information by reflecting the infrared radiation out of a substrate surface^[24]. The 3D scanning has a 100 W laser supply, a 5-megapixel depth vision, a diagonally reading length of 90-600 mm, and a precision of 5-12 m. Utilizing the manufacturer-provided application, all scanners of each impression's models being combined from top to bottom from bottom to top. To facilitate new eyeball manufacturing on 3D printable ophthalmic prostheses, the eyeball centre inscription on the impressions mould were visually digitized alongside the mould.

The scanning picture is created using photographs that are detected from multiple angles, as a consequence, the final picture may have artifacts that needed to be

eliminated in order to create the 3D models. This has been accomplished by removing the interior but also exterior distortion of twisting models that use the mending wizards' tool in a visual premiere. The impressions photographer's texture had also been smoothed using the programmed^[25,26]. To avoid creating the breach inside its modeling

data, the hexagon was distributed equally using the ZR emesher product then the surfaces being smoothed out utilizing the polish applicator. The stereo lithography (STL) document was created using that changed 3D design input, then this was saved.

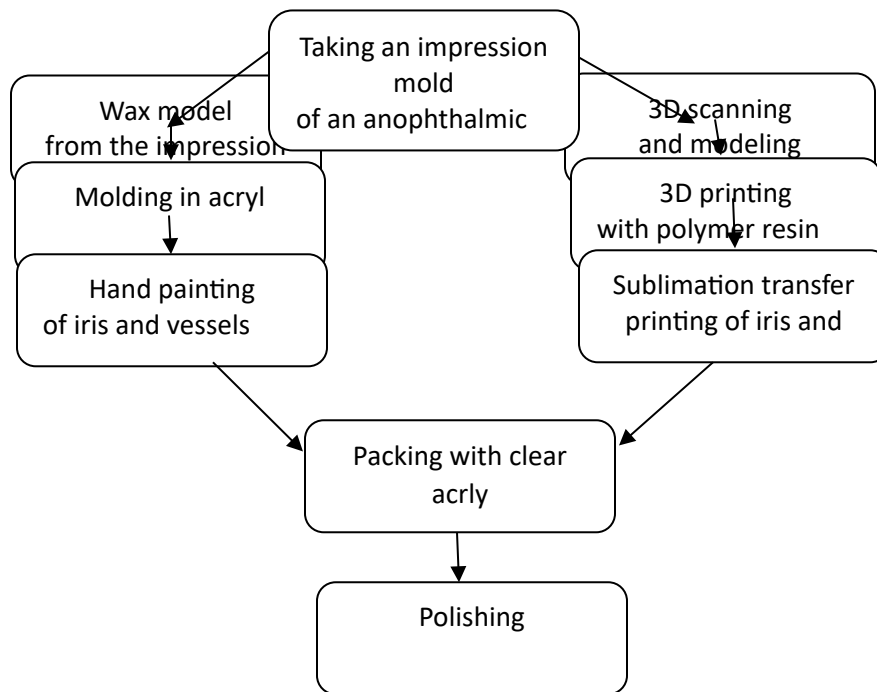


Figure 2: 3D printer techniques

3.2 3D printing of the ocular prosthesis

A digital light processing (DLP) technology with such 50- μ m accuracy throughout the X-Y planes were utilized in these tasks. The depth, or the Z-axis, may well be adjusted in denominations of 25 μ m (i.e., 25 μ m, 50 μ m, and 75 μ m). As the foundation, they employed a biodegradable photocurable polymer. White was chosen as the color of the polymer since it most accurately represents the color of the conjunctiva of the eye.

The lower adherence became a concern since the hypoallergenic molecule's thickness being greater than that advised either by 3D photocopier developer. The stickiness for

both the materials was decreased, which increased the manufacturing consistency; by fastening a warming surface towards its accent tables its adhesive in the 3d printing machine^[27]. The resin's inclination of cure got then examined, and its thicknesses were assessed in order to determine the proper quantity of sunlight for the molding period depending on the properties of the component.

Whenever this technique was established, it produced a single slicing template with all of the information from the 3D designer. After that, the implanted ophthalmic prosthesis' securing was removed, and the margins were

cleaned with wine to remove the remaining resin. The prostheses were then heated to 170 °C for 30 minutes and then post-heated to 100 °C for two hours. These ophthalmic prosthetic impressions design in 3D.

It took about 30 minutes to get a 3D scan of the imprint mould. The three - dimensional data has to be altered utilizing graphical applications for an additional 30 minutes. This traditional process, on that other hand, takes around an hour to create a plaster cast again from image mould. Although all processes take the similar duration of time to finish, scanning technology is an advanced method which does not necessitate human jobs^[28]. This program may also being used to construct a database of individual ophthalmic prosthesis. As Fig. 3, an ophthalmic connector imprint mould, three - dimensional data, as well as its altered picture are displayed (a-

and brightness parameters that correspond to the properties of the target surface. The technology in question has been initially intended to work with a supporting structure that had a stiffness of between 100 and 120 mPas. As a result, the printouts dissolved throughout publishing because the biomedical substance employed in this research exhibited a lower sticking (680–720 mPas) and a greater stickiness. In order to establish a thermal difference between 50–60 °C, a warming panel were attached to the platter to stabilize production^[29]. The produced ophthalmic prostheses appear as Figure. 3. Together with the 3D photocopier tech specs, which were listed in Table 1. (d). That ophthalmic prostheses were printed using a 3D modeling in about 45 minutes as compared to physically making an acetate mould using the traditional method, typically lasted about an hour. The ophthalmic prostheses that were 3D manufactured weighted around 2 g.

To acquire the best results, a DLP projector must be configured with specific brightness

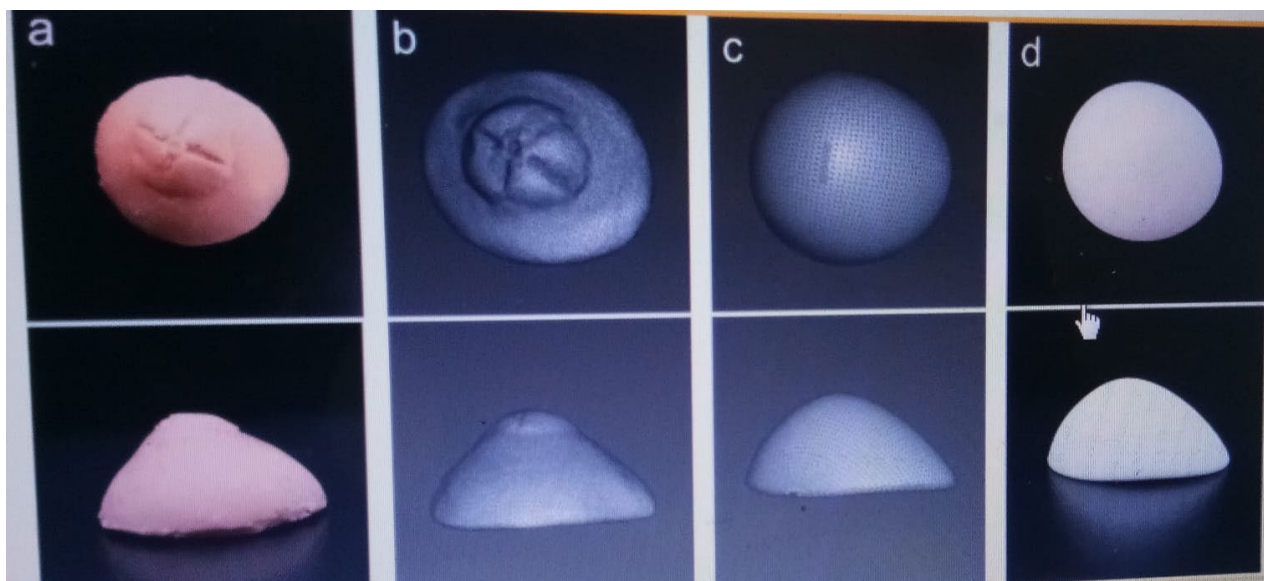


Figure 3: Three-dimensional (3D) model of impression mold of patient’s anophthalmic socket and 3D printed output. (a) Impression mold of patient’s anophthalmic socket obtained by following the conventional protocol for manufacturing an ocular prosthesis. (b) Optical scan of the impression mold using a 3D scanner, and (c) modified and smoothed image to reduce artifacts. (d) 3D printed output of ocular prosthesis printed using a DLP printer

Table 1: Technical parameter of the 3D printer used in this study

Initial exposure time (three layers)	30 s
Energy density	3.0 mW/cm ²
Layer thickness	50 μm
Basic exposure time	2 s
XY resolution	50 μm

4 Procedures of eye prosthesis construction

A synthetic eyeball is used to replace a biological eye that has been destroyed due to an illness and accident. The implant fills the orbital bone depression or improves appearance despite its inability to restore vision. Prior to the development of prosthetic eyes, somebody who had lost an eye would often wear a patch. For enable eye movement, a synthetic eyeball may be fastened to the musculature inside the socket. The majority of synthetic eyeballs used nowadays is constructed of plastics and have a lifespan of around a decades^[30]. According with their fast development fluctuations, kids need their prostheses replaced more frequently. Throughout birth through maturity, quite so many as four or five prosthesis can be needed.

According to the Association for the Prevention of Vision Loss, between 10,000 and 12,000 people lose an eye annually. A variety of genetic diseases may result in eye impairment and necessitate the use of an synthetic eyeball, even although mishaps account for at least 50% of all ocular loss (in one research, more men lost their eyes to injuries than females)^[31]. Microphthalmia is a congenital condition in which the eye doesn't really mature to its regular size for an unidentified cause. These eyes are completely blind, and at most, they may be able to perceive some light.

Additionally, some individuals are born without either one or both eyes. Anophthalmia is one of the characteristics that make correctly installing a synthetic

eyeball a most challenging. The first process might sometimes take a year or longer. Surgery may be required in specific circumstances.

A genetic (present at birth) malignancy or tumor, melanoma is often hereditary. One in fourth, or 25%, of those who have this illness in only single eye will transmit it along to their offspring. 50% of cases include both eyeballs having tumors. Vision problems or hypertension are two more genetic disorders that result in eye loss. According to poll, 63% of vision impairment caused by illness happens prior to actually the age of 50. The defective and injured eyeball may be replaced in 2 stages^[32]. An optometrist or ophthalmology first should remove the normal eye. Two different sorts of procedures exist. By removing the tendons that are attached to the cornea during the surgical excision, the eye is removed (white of eyeball). After severing the visual cortex, a surgeon extracts the eye from its receptacle. After inserting an implantation to replace lost volumes or provide the prosthetic eye with considerable mobility, this incision is subsequently stitched up.

The cells of the eyeball are taken out during excoriation.

The eyeball's contents are taken out during the procedure after the physician creates a slit surrounding the iris. Each eyeball is then filled with silicon, crystal, and other inert substance, as well as the incision is stitched up. The surgeon may insert a conformer, a silicone disc, into the sockets after the procedure. The conformer keeps the sockets

from contracting or maintains enough spaces for the prosthesis^[33]. Rigid plastics and silicone are used to make conformers. The individual needs 4 to 6 weeks to recover following surgery. An expert ocularist subsequently creates or fits the prosthetic eye. It was decided to use an old conformer and standard plastic ophthalmic imprint trays to fit within the aperture. To give the realistic draping all materials, or individual must remain in a slight bow. Changes were performed to reduce potential over extensions to attain the proper shape or contours of the eyes^[34]. To avoid causing any discomfort to the muscles within the sockets, the edges were smoothed using a polishing.

5-Raw Materials

The prosthetic eye is mostly made of silicone. When create these moulds, waxes or plaster of Paris are utilized. Alginate, a white powder, is utilized in the compression molding. This prosthetic is decorated with acrylics as well as other substances to give it realistic qualities. An optical prosthetic should remain to progress, that will be advantageous to the patients as well as the ocularist. Numerous changes have already taken place in recent decades^[35]. The user may choose between two distinct pupil sizes on a prosthetic that was created in the earlier 1980s. During the same time, a special contact lens with a sizable black pupil was created, which just lies on the synthetic eyes corneal.

6.The main difference between digital and conventional methods of eye prosthesis construction

Humans has understood how to create synthetic eyes from the era of the ancient Egyptians or Peruvian Indians, however it was not until World War II that the advancement of advanced polymers was utilized as well as led to the creation of successful aesthetic ophthalmic prostheses. Congenital defects, irreversible injuries, tumors, sympathetic eye infections, severe blindness, or the necessity for histological verification of a suspected disease can all result in the loss and disappearance of an eye, which can have aesthetic or psychological implications. Evisceration, enucleation, and exenteration are the 3 surgical management strategies that can be used, based on the seriousness of the condition. Evisceration, or rather the evacuation of the material of the sphere while keeping the conjunctiva (and occasionally the corneal) untouched, is the least invasive laparoscopic procedure^[36]. The world as well as a part of a visual cortex is surgically removed from the orbital by surgical excision. The most extreme procedure is exenteration, which involves emptying the orbits of all its materials. The preferred method of therapy to enable the patient to resume their regular line of work is a prosthesis substitution that creates a respectable or realistic look. The consisting of at least must have thorough comprehension of or dedication to this type of therapy. Inside the research, a variety different manufacturing methods of ophthalmic prostheses had being documented. Each method has advantages as well as disadvantages. For transmit stress evenly, direct contact between the eye prosthetic as well as the tissues substrate is required. A manufactured prosthetic should thus be disregarded. To match the prosthetic' color to the native sclera, one must have

strong creative ability to use the standard varnish procedure^[37]. Despite a premade prosthetic, it offers excellent aesthetic benefits that precisely conforms to the cell substrate. However, this method calls for additional chair-side time. Digital imaging techniques offer appropriate aesthetics since they only slightly alter the undamaged eye. The method is extremely easy to use, involves less creative ability, and takes less time to complete. However, editing or modifying such photographs calls both a high-quality digital camera as well as a working understanding of some simple programs.

Secular prosthesis may be created to order or are already produced (stock). Whenever there is a shortage of time or money is an issue, the usage of a standard prosthetic is often advised. Nevertheless, if an appropriate iris assortment is needed, a sizable but costly stock of ready-made prosthesis is necessary. After that, the sockets should be fitted with the prostheses. The most effective optical replacement was shown to become the personally handcrafted, made - to - order plastic polymer synthetic eye. Nevertheless, customized construction requires the expertise of a trained painter for the replication of the iris or sclera it is a labor-intensive operation that takes time. There are occasions when generic prosthesis in common sizes, shapes, or colors might fill the necessity for a synthetic eye. This prosthesis may be applied preoperatively or postoperatively^[38]. Manufacturing calls absolutely no specialized knowledge or supplies. Stock prosthesis may be provided rapidly and thus are reasonably priced. Although the time spent inside the clinical as well as laboratory is not significantly shorter than the period needed to create a personalized ophthalmic prosthesis, the outcome is seldom the same. An ocular prosthesis made to order may be

built with many variants. The implant's full capacity is used to induce motion because of the intimate adaptability to the cell bed. Hence, this term "implants" refers to a solid object that is utilized to replace lost orbital bone capacity and improve the outlook for the ensuing prosthetic. Nevertheless, the use of these devices could only be permitted in situations where significant amounts of deeper tissues were surgically removed. It is less common for excludes to gather mucous or detritus, that might aggravate mucosal and serve as a possible cause of disease. A personalized ophthalmic prosthetic' best aesthetic or practical outcomes facilitate the patient's return to a regular life routine. However, a personalized prosthesis is more costly than a stock prosthetic as well as must be made in a number of processes. Glasses and methyl methacrylate resin are also acceptable materials for the ocular prosthetic. Glass is not the preferred materials since it has a short useable life span of between 18 or 24 months due to fracture or coating degeneration from interaction with orbiting elements^[39]. In terms of cellular compliance, aesthetic characteristics, endurance, color persistence, flexibility of shape, affordability, and accessibility, methyl methacrylate resin is preferable to alternative ophthalmic prosthesis materials. The skill of creating personalized eye prostheses is detailed throughout writings to use a variety of approaches.

The two most popular methods for creating personalized ocular prostheses are described in this research, along with the benefits or drawbacks of each method. The second approach highlights the necessity for handcrafted attachments, rendering the treatment much cheaper for the individual, whereas the first method emphasizes the ease of the operation by employing ready-made equipment for construction.

Severe medical or psychological issues may result from the deformity brought on by the

removal of an eye. The majority of sufferers go through a lot of anxiety, mostly adapting to a functional disability brought on by the lost eye as well as to social responses. Reconstruction of the damaged eyeball is therefore required to aid inside the person's physiological or mental recovery as well as to increase social acceptability. It is occasionally possible to get a stock prosthetic in the required sizes, shapes, or colors to replace a missing eye. There are no specialized tools or content required to fabricate a stock ophthalmic eye. People are reasonably priced, as well as the complete procedure takes less time. Nevertheless, inside the preponderance of hydrolysis reaction instances, a tailored ocular prosthetic is beneficial because it offers with acrylic and oil paint were offered in a number of researches that suggested prosthetic iris replication. However, a majority of these methods take a lot of effort or rely on the user's creative abilities and knowledge of color theory^[41]. Maxillofacial rehabilitation's primary goal is to imitate nature. By order to include genuine aesthetics, the essay aims that streamline the creation of ophthalmic prostheses using digital imaging.

Regarding individuals experiencing visual defects, achieving an aesthetic result depends critically on an exact iris replication during the construction of the visual prosthetic. Thus, a straightforward method for creating the ocular prosthesis has been proposed. For the recovery process, the computerized image of the person's actual eye is used^[42]. From the perspectives on patient acceptance, comfort, or aesthetics, the method had produced positive outcomes. For an additional stage towards individualized aesthetics, both cornea and iris should be digitally photographed as part of the aforesaid method.

Ocular prosthesis has a rich history of effective usage, and throughout time,

greater adaptability to a damaged tissue, higher mobility, or tolerable aesthetics thanks to a good fit between the iris or sclera's color and size. However, a personalized prosthetic is more costly than just a standard prosthetic it must be made in a number of processes. This same eye is an even organ, making replication difficult^[40]. The ophthalmic prosthetic should resemble the native eye as closely as feasible, particularly in terms of the iris, that controls the color of the eyes.

A crucial stage in the creation of an optical prosthesis is the replication of the artificial iris. With the aid of all possible technological or creative skills, it was completed. For example, white cardboard with watercolor paint or black cardboard

modifications to the methods or components have been made. This approach is a suitable replacement for more labor-intensive traditional techniques of making ocular prosthesis because of benefits including short processing times or enhanced ease.

6.1 Traditional Technique for Making Custom-Made Eyewear

Prosthesis The effectiveness of a prosthetic usually starts with a precise imprint of the area that has to be repaired. An correct record of a anterior wall, the palpebrae's location in respect to the wall, as well as the superior or inferior image on a particular of the palpebrae are essential requirements for an excellent imprint. This might be documented in a variety of ways^[43].

- 1) External and direct impressions
- 2) Imprint using a standard and customized standard optical tray
- 3) Impressions made using a generic ophthalmic prosthetic
- 4) Using a wax sclera blank
- 5) Obtaining a face imprint to create a unique occlusion tray that may be utilized to prepare divided casts. However just before a creating an effect, the sufferer must be told regarding

their claustrophobic or acrophobia as well as advised to calm down.

When the imprint materials set, metal wire loops are put over the imprint to help with preservation, and afterwards plaster is applied to the impressions to support it. This imprint substance is a light-bodied elastomeric, which is inserted inside the left eyeball sockets. Following the imprint has been removed from the eye; it is boxed, first with medical or dental stones to the height of the contours, as well as then with dying stones to create a two-piece mould. Wax pattern prototype is completed, an equity cornea is chosen that matches the second part consisted as well as iris-pupil complicated of a dorsolateral instinctual eye, or it is carefully cut to accurately fit into the connector^[44]. Next, characterized staining is completed in accordance with the sequence, as well as try-in is completed. The insertion of wax corrects the eye's protrusion. As once proper bulge has been achieved, the prosthetic' tissue side is once more retro fitted with fascial conditioners as well as inserted into the sockets to capture the eye's operational motions. The relined tissue side of the optical prosthetic is filled with heat-cured transparent composite resins, benefits of the procedure, or compressed before cure. Deflasking is completed once the flasks have cooled, as well as the prosthetic is then detached from the investing or finished. The polishing prosthetic should be smooth or devoid of any rough edges that might aggravate the orbital bone or promote fluids to build up for further discomfort.

The finished prosthetic is cleaned in a combination of 0.5% chlorhexidine or 70% isopropanol approximately 5 minutes before to being implanted^[45]. Following cleaning, the prosthetic is washed in sterile saline solution to avoid chemicals sensitivity. The optical prosthetic is then given, while immediately after the incident directions are provided.

6.3 Digital photography technique:

Up towards the iris placement, every step followed a standard process.

- A customized tray with an additional silicon lighting body is used to create the impression.
- Then, a wax conformer was made or tested on the individual.
- To get conjunctival blanks, this is deposited or packaged. The Graph Grid is used to locate the iris.
- Each patient's undamaged eyeball is captured in a high-quality shot using a DSLR camera.
- The diameter of the cornea or eyeball was significantly changed, as well as the contrast or brightness of such a shot utilizing editor. This picture was produced on self-adhesive shiny plastic material.
- The conjunctival blanks were then tested or corrected inside the patient's eye, as well as the highest rating decal to the undamaged retina is chosen, as it is then pasted on the template.
- This prosthetic is covered with a transparent protective coating (G Coat) afterwards being judged on aesthetics. The individual was subsequently given the prosthetic.

Conclusion

Our research provides proof that 3D-printed ocular prosthesis made utilizing computer-aided modeling technologies as well as a sublimated process are both biologically or physiochemical acceptable. Using a research, it demonstrated that the 3D printed optical prosthetic was satisfactory in functionality or aesthetics based on individual surveys as well as the opinions of a ophthalmologists/oculists.

Conflicts of Interest

The authors declare that they have no conflicts of interest.

Funding

This research received no external funding.

Data Availability Statement

Data are available from the authors upon reasonable request.

Acknowledgments

The authors would like to thank Department of Prosthetic Dental Techniques, College of Health and Medical Techniques, Middle Technical University, Baghdad, Iraq, for their support in the present work.

References

1. Hatamleh MM, Abbariki M, Alqudah N, Cook AE. Survey of ocular prosthetics rehabilitation in the United Kingdom, part 1: Anophthalmic patients' aetiology, opinions, and attitudes. *J Craniofac Surg.* 2017;28(5):1293-1296. <https://doi.org/10.1097/SCS.0000000000003370>
2. Santos DM, Nagay BE, da Silva EV, Bonatto Lda R, Sonogo MV, Moreno A, Rangel EC, da Cruz NC, Goiato MC. In vitro analysis of different properties of acrylic resins for ocular prosthesis submitted to accelerated aging with or without photopolymerized glaze. *Mater Sci Eng C Mater Biol Appl.* 2016;69:995-1003. <https://doi.org/10.1016/j.msec.2016.07.081>
3. Othayoth AK, Srinivas B, Murugan K, Muralidharan K. Poly(methyl methacrylate)/polyphosphate blends with tunable refractive indices for optical applications. *Opt Mater.* 2020;104:109841. <https://doi.org/10.1016/j.optmat.2020.109841>
4. Patel S, Tutchenko L. The refractive index of the human cornea: A review. *Cont Lens Anterior Eye.* 2019;42(6):575-580. <https://doi.org/10.1016/j.clae.2019.04.018>
5. Chae MP, Rozen WM, McMenamin PG, Findlay MW, Spychal RT, Hunter-Smith DJ. Emerging Applications of Bedside 3D Printing in Plastic Surgery. *Front Surg.* 2015;2:25. <https://doi.org/10.3389/fsurg.2015.00025>
6. Hoy MB. 3D printing: making things at the library. *Med Ref Serv Q.* 2013;32(1):94-99. <https://doi.org/10.1080/02763869.2013.749139>
7. Huang W, Zhang X. 3D Printing: Print the future of ophthalmology. *Invest Ophthalmol Vis Sci.* 2014;55(8):5380-5381. <https://doi.org/10.1167/iovs.14-15231>
8. Hoang D, Perrault D, Stevanovic M, Ghiassi A. Surgical applications of three-dimensional printing: a review of the current literature & how to get started. *Ann Transl Med.* 2016;4(23):456. <https://doi.org/10.21037/atm.2016.12.18>
9. Marro A, Bandukwala T, Mak W. Three-Dimensional Printing and Medical

- Imaging: A Review of the Methods and Applications. *Curr Probl Diagn Radiol.* 2016;45(1):2-
9. <https://doi.org/10.1067/j.cpradiol.2015.07.009>
10. Ruiters S, Sun Y, de Jong S, Politis C, Mombaerts I. Computer-aided design and three-dimensional printing in the manufacturing of an ocular prosthesis. *Br J Ophthalmol.* 2016;100(7):879-881. <https://doi.org/10.1136/bjophthalmol-2016-308399>
11. Alam MS, Sugavaneswaran M, Arumaikkannu G, Mukherjee B. An innovative method of ocular prosthesis fabrication by bio-CAD and rapid 3-D printing technology: A pilot study. *Orbit.* 2017;36(4):223-227. <https://doi.org/10.1080/01676830.2017.1287741>
12. Chen J, Wu X, Wang MY, Li X. 3D shape modeling using a self-developed handheld 3D laser scanner and an efficient HT-ICP point cloud registration algorithm. *Opt Laser Technol.* 2013;45:414-423. <https://doi.org/10.1016/j.optlastec.2012.06.015>
13. Ko J, Kim SH, Baek SW, Chae MK, Yoon JS. Hydrophilic surface modification of poly(methyl methacrylate)-based ocular prostheses using poly(ethylene glycol) grafting. *Colloids Surf B Biointerfaces.* 2017;158:287-294. <https://doi.org/10.1016/j.colsurfb.2017.07.017>
14. Petrovic V, Gonzalez JVH, Ferrando OJ, Gordillo JD, Puchades JRB, Grinan LP. Additive layered manufacturing: sectors of industrial application shown through case studies. *Int J Prod Res.* 2011;49(4):1061-1079. <https://doi.org/10.1080/00207540903479786>
15. Finnes T. High Definition 3D Printing- Comparing SLA and FDM Printing Technologies. *J Undergrad Res.* 2015;13:3.
16. Lee JY, Tan WS, An J, Chua CK, Tang CY, Fane AG, Chong TH. The potential to enhance membrane module design with 3D printing technology. *J Memb Sci.* 2016;499:480-490. <https://doi.org/10.1016/j.memsci.2015.11.008>
17. Park JH, Jung JW, Kang HW, Cho DW. Indirect three-dimensional printing of synthetic polymer scaffold based on thermal molding process. *Biofabrication.* 2014;6(2):025003. <https://doi.org/10.1088/1758-5082/6/2/025003>
18. Mitteramskogler G, Gmeiner R, Felzmann R, Gruber S, Hofstetter C, Stampfl J, Ebert J, Wachter W, Laubersheimer J. Light curing strategies for lithography-based additive manufacturing of customized ceramics. *Addit Manuf.* 2014;1:110-118. <https://doi.org/10.1016/j.addma.2014.08.003>
19. Kang HW, Cho DW. Development of an indirect stereolithography technology for scaffold fabrication with a wide range of

- biomaterial selectivity. *Tissue Eng Part C Methods*. 2012;18(9):719-729. <https://doi.org/10.1089/ten.tec.2011.0621>
20. Kan CW. CO2 laser treatment as a clean process for treating denim fabric. *J Clean Prod*. 2014;66:624-631. <https://doi.org/10.1016/j.jclepro.2013.11.054>
21. Burge D, Gordeladze N, Bigourdan JL, Nishimura D. In: NIP & Digital Fabrication Conference. Society for Imaging Science and Technology; 2005:205-208.
22. Salesin E, Burge D. In: NIP & Digital Fabrication Conference. Society for Imaging Science and Technology; 2006:197-200.
23. Raj N, Singh M, Raj V, Anwar M, Kumar L. Prevalence of ocular defects among patients visiting in an institutionalized hospital setting: A cross-sectional study. *Natl J Maxillofac Surg*. 2016;7(1):67-70. <https://doi.org/10.4103/0975-5950.196131>
24. Kord Valeshabad A, Naseripour M, Asghari R, Parhizgar SH, Parhizgar SE, Taghvaei M, Miri S. Enucleation and evisceration: Indications, complications and clinicopathological correlations. *Int J Ophthalmol*. 2014;7(4):677-680.
25. Yousuf SJ, Jones LS, Kidwell ED Jr. Enucleation and evisceration: 20 years of experience. *Orbit*. 2012;31(4):211-215. <https://doi.org/10.3109/01676830.2011.639477>
26. Sabel BA, Wang J, Cárdenas-Morales L, Faiq M, Heim C. Mental stress as consequence and cause of vision loss: The dawn of psychosomatic ophthalmology for preventive and personalized medicine. *EPMA J*. 2018;9(2):133-160. <https://doi.org/10.1007/s13167-018-0136-8>
27. Goiato MC, Nicolau EI, Mazaro JV, Dos Santos DM, Vedovatto E, Zavanelli AC, Filho HG, Pellizzer EP. Mobility, aesthetic, implants, and satisfaction of the ocular prostheses wearers. *J Craniofac Surg*. 2010;21(1):160-164. <https://doi.org/10.1097/SCS.0b013e3181cfe898>
28. Amornvit P, Rokaya D, Shrestha B, Srithavaj T. Prosthetic rehabilitation of an ocular defect with post-enucleation socket syndrome: A case report. *Saudi Dent J*. 2014;26(1):29-32. <https://doi.org/10.1016/j.sdentj.2013.12.006>
29. Cevik P, Dilber E, Eraslan O. Different techniques in fabrication of ocular prosthesis. *J Craniofac Surg*. 2012;23(6):1779-1781. <https://doi.org/10.1097/SCS.0b013e31826701bb>
30. Sethi T, Kheur M, Haylock C, Harianawala H. Fabrication of a custom ocular prosthesis. *Middle East Afr J Ophthalmol*. 2014;21(3):271-274. <https://doi.org/10.4103/0974-9233.134694>

31. Ko J, Kim SH, Baek SW, Chae MK, Yoon JS. Semi-automated fabrication of customized ocular prosthesis with three-dimensional printing and sublimation transfer printing technology. *Sci Rep*. 2019;9(1):2968. <https://doi.org/10.1038/s41598-019-38992-y>
32. Lanzara R, Thakur A, Viswambaran M, Khattak A. Fabrication of ocular prosthesis with a digital customization technique-a case report. *J Family Med Prim Care*. 2019;8(3):1239-1242. <https://doi.org/10.4103/jfmprc.13319>
33. Dave TV, Nayak A, Palo M, Goud Y, Tripuraneni D, Gupta S. Custom ocular prosthesis-related concerns: Patient feedback survey-based report vis-à-vis objective clinical grading scales. *Orbit*. 2021;40(5):357-363. <https://doi.org/10.1080/01676830.2020.1797826>
34. Shrivastava S, Agarwal S, Shrivastava KJ, Tyagi P. Custom-made ocular prosthesis for a pediatric patient with unilateral anophthalmia: A case report. *J Indian Soc Pedod Prev Dent*. 2013;31(3):194-196. <https://doi.org/10.4103/0970-4388.117973>
35. Da Costa GC, Aras MA, Chalakkal P, Da Costa MC. Ocular prosthesis incorporating ips e-max press scleral veneer and a literature review on non-integrated ocular prosthesis. *Int J Ophthalmol*. 2017;10(1):148-156.
36. Moreno A, Goiato MC, Oliveira KF, Iyda MG, Haddad MF, de Carvalho Dekon SF, dos Santos DM. Color stability of the artificial iris button in an ocular prosthesis before and after acrylic resin polymerization. *Cont Lens Anterior Eye*. 2015;38(5):414-418. <https://doi.org/10.1016/j.clae.2015.05.003>
37. Moreno A, Goiato MC, dos Santos DM, Haddad MF, Pesqueira AA, Bannwart LC. Effect of different disinfectants on the microhardness and roughness of acrylic resins for ocular prosthesis. *Gerodontology*. 2013;30(1):32-39. <https://doi.org/10.1111/j.1741-2358.2012.00642.x>
38. Bannwart LC, Goiato MC, dos Santos DM, Moreno A, Pesqueira AA, Haddad MF, Andreotti AM, de Medeiros RA. Chromatic changes to artificial irises produced using different techniques. *J Biomed Opt*. 2013;18(5):058002. <https://doi.org/10.1117/1.JBO.18.5.058002>
39. Zafar MS. Prosthodontic applications of polymethyl methacrylate (PMMA): An update. *Polymers*. 2020;12(10):2299. <https://doi.org/10.3390/polym12102299>
40. de Ortueta D, Rüdén D, Magnago T. Influence of stromal refractive index and hydration on corneal laser refractive surgery. *J Cataract Refract Surg*. 2014;40(6):897-904. <https://doi.org/10.1016/j.jcrs.2013.07.050>

41. Smadja D, Zalevsky Z, Lellouche J-P. Nano-drops for nearsightedness and farsightedness. [Phys.org](https://www.phys.org). 2018.

42. Knox WH, Huxlin KR. Method for modifying the refractive index of ocular tissues. US Patent 8,617,147 B2.